

# 8

## Muscular System

**DOUBLE THE MUSCLE.** The newborn had an astonishing appearance—his prominent arm and thigh muscles looked as if he'd been weight-lifting in the womb. By five years of age, his muscles twice normal size, he could lift heavier weights than could many adults. He also had half the normal amount of body fat.

The boy's muscle cells cannot produce a protein called myostatin, which normally stops stem cells from making a muscle too large. In this boy a mutation turned off this genetic brake, and as a result his muscles bulge, their cells both larger and more numerous than those in the muscles of a normal child. The boy is healthy so far, but because myostatin is also made in cardiac muscle, he may develop heart problems.

Other species with myostatin mutations are well known. Naturally "double-muscled" cattle and sheep are valued for their high weights early in life. Chicken breeders lower myostatin production to yield meatier birds, and "mighty mice" with silenced myostatin genes are used in basic research to study muscle overgrowth. In clinical applications, researchers are investigating ways to block myostatin activity to stimulate muscle growth to reverse muscle-wasting from AIDS, cancer, and muscular dystrophy. Myostatin is also of interest in athletics. Theoretically, infants could be tested to identify those with myostatin gene variants that predict athletic prowess, given the right training. Myostatin could also be abused to enhance athletic performance.



*For those of us not endowed with genetically doubled muscles, regular resistance training (weight lifting) can tone muscles and trim fat.*

For those of us not endowed with double-muscle mutations, resistance (weight) training can increase the ratio of muscle to fat in our bodies, which offers several benefits. Because muscle burns calories at three times the rate of fat, a lean body is more energetically efficient. Weight-lifting increases muscle tone and bone density; lowers blood pressure; decreases the risks of developing arthritis, osteoporosis, and diabetes mellitus; and is even associated with improved self-esteem and fewer sick days.

### Learning Outcomes

*After studying this chapter, you should be able to do the following:*

#### 8.1 Introduction

1. List various outcomes of muscular actions. (p. 177)

#### 8.2 Structure of a Skeletal Muscle

2. Describe how connective tissue is part of a skeletal muscle. (p. 177)
3. Name the major parts of a skeletal muscle fiber, and describe the function of each. (p. 177)
4. Discuss nervous stimulation of a skeletal muscle. (p. 180)

#### 8.3 Skeletal Muscle Contraction

5. Identify the major events of skeletal muscle fiber contraction. (p. 181)

6. Describe the energy sources for muscle fiber contraction. (p. 183)

7. Describe how oxygen debt develops and how a muscle may become fatigued. (p. 184)

#### 8.4 Muscular Responses

8. Distinguish between a twitch and a sustained contraction. (p. 187)
9. Explain how muscular contractions move body parts and help maintain posture. (p. 188)

#### 8.5 Smooth Muscle

10. Distinguish between the structures and functions of multiunit smooth muscle and visceral smooth muscle. (p. 189)

11. Compare the contraction mechanisms of skeletal and smooth muscle fibers. (p. 189)

#### 8.6 Cardiac Muscle

12. Compare the contraction mechanisms of cardiac and skeletal muscle fibers. (p. 190)

#### 8.7 Skeletal Muscle Actions

13. Explain how the attachments, locations, and interactions of skeletal muscles make possible certain movements. (p. 192)

#### 8.8 Major Skeletal Muscles

14. Describe the locations and actions of the major skeletal muscles of each body region. (p. 193–205)

## Aids to Understanding Words

(Appendix A on page 567 has a complete list of Aids to Understanding Words.)

**calat-** [something inserted] *intercalated* disc: Membranous band that connects cardiac muscle cells.

**erg-** [work] *synergist*: Muscle that works with a prime mover to produce a movement.

**hyper-** [over, more] muscular *hypertrophy*: Enlargement of muscle fibers.

**inter-** [between] *intercalated* disc: Membranous band that connects cardiac muscle cells.

**laten-** [hidden] *latent* period: Time between application of a stimulus and the beginning of a muscle contraction.

**myo-** [muscle] *myofibril*: Contractile structure within a muscle cell.

**sarco-** [flesh] *sarcoplasm*: Material (cytoplasm) within a muscle fiber.

**syn-** [together] *synergist*: Muscle that works with a prime mover to produce a movement.

**tetan-** [stiff] *tetanic* contraction: Sustained muscular contraction.

**-troph** [well fed] muscular *hypertrophy*: Enlargement of muscle fibers.

## 8.1 INTRODUCTION

Talking and walking, breathing and sneezing—in fact, all movements—require muscles. Muscles are organs composed of specialized cells that use the chemical energy stored in nutrients to contract. Muscular actions also provide muscle tone, propel body fluids and food, generate the heartbeat, and distribute heat.

Muscles are of three types—skeletal muscle, smooth muscle, and cardiac muscle. This chapter focuses mostly on skeletal muscle, which attaches to bones and is under conscious control. Smooth muscle and cardiac muscle are discussed briefly.

nective tissue, therefore, enclose and separate all parts of a skeletal muscle. This organization allows the parts to move somewhat independently. Many blood vessels and nerves pass through these layers.

A tendon, the attachment of a muscle to a bone, may become painfully inflamed and swollen following injury or the repeated stress of athletic activity, a condition called *tendinitis*. When the inflammation occurs in the connective tissue sheath of the tendon (the *tenosynovium*), it is called *tenosynovitis*. The tendons most commonly affected are those associated with the joint capsules of the shoulder, elbow, and hip and those that move the hand, thigh, and foot.

## 8.2 STRUCTURE OF A SKELETAL MUSCLE

A skeletal muscle is an organ of the muscular system. It is composed of skeletal muscle tissue, nervous tissue, blood, and other connective tissues.

### Connective Tissue Coverings

Layers of fibrous connective tissue called **fascia** (fash'e-ah) separate an individual skeletal muscle from adjacent muscles and hold it in position (fig. 8.1). This connective tissue surrounds each muscle and may project beyond its end to form a cordlike tendon. Fibers in a tendon may intertwine with those in a bone's periosteum, attaching the muscle to the bone. In other cases, the connective tissue forms broad fibrous sheets called **aponeuroses** (ap'o-nu-ro'sez), which may attach to bone or to the coverings of adjacent muscles (see figs. 8.17 and 8.19).

The layer of connective tissue that closely surrounds a skeletal muscle is called *epimysium* (fig. 8.1). Other layers of connective tissue, called *perimysium*, extend inward from the epimysium and separate the muscle tissue into small compartments. These compartments contain bundles of skeletal muscle fibers called *fascicles* (fasciculi). Each muscle fiber within a fascicle (fasciculus) lies within a layer of connective tissue in the form of a thin covering called *endomysium*. Layers of con-

### Skeletal Muscle Fibers

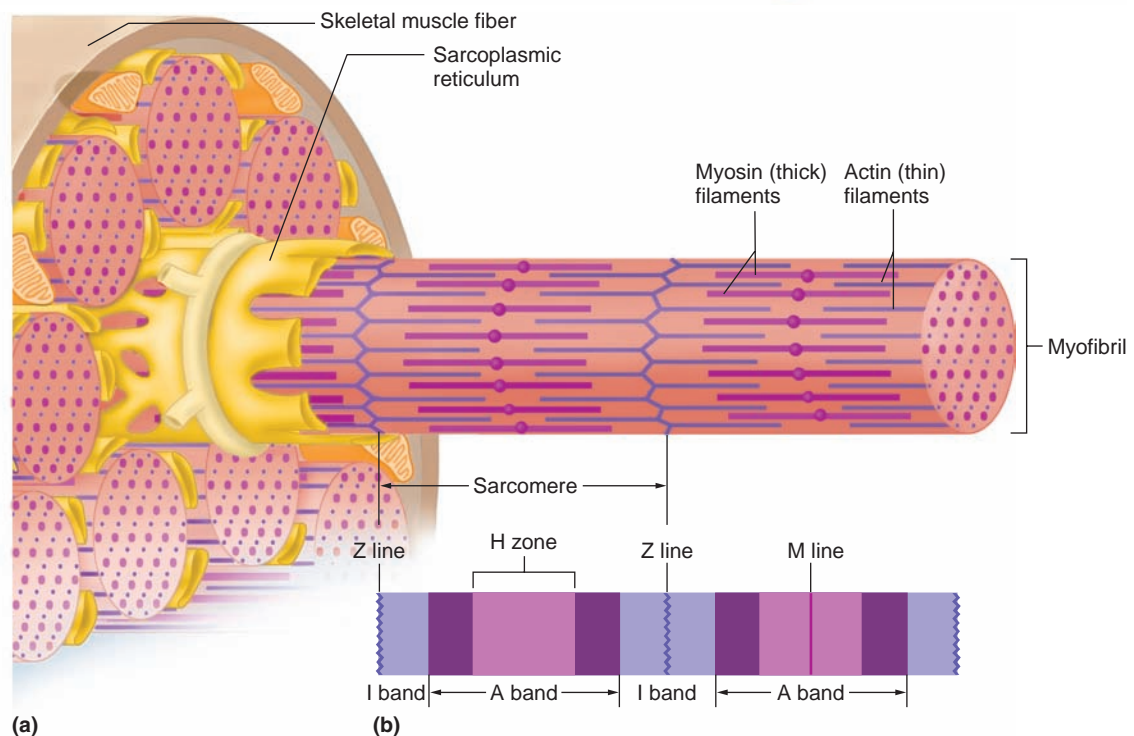
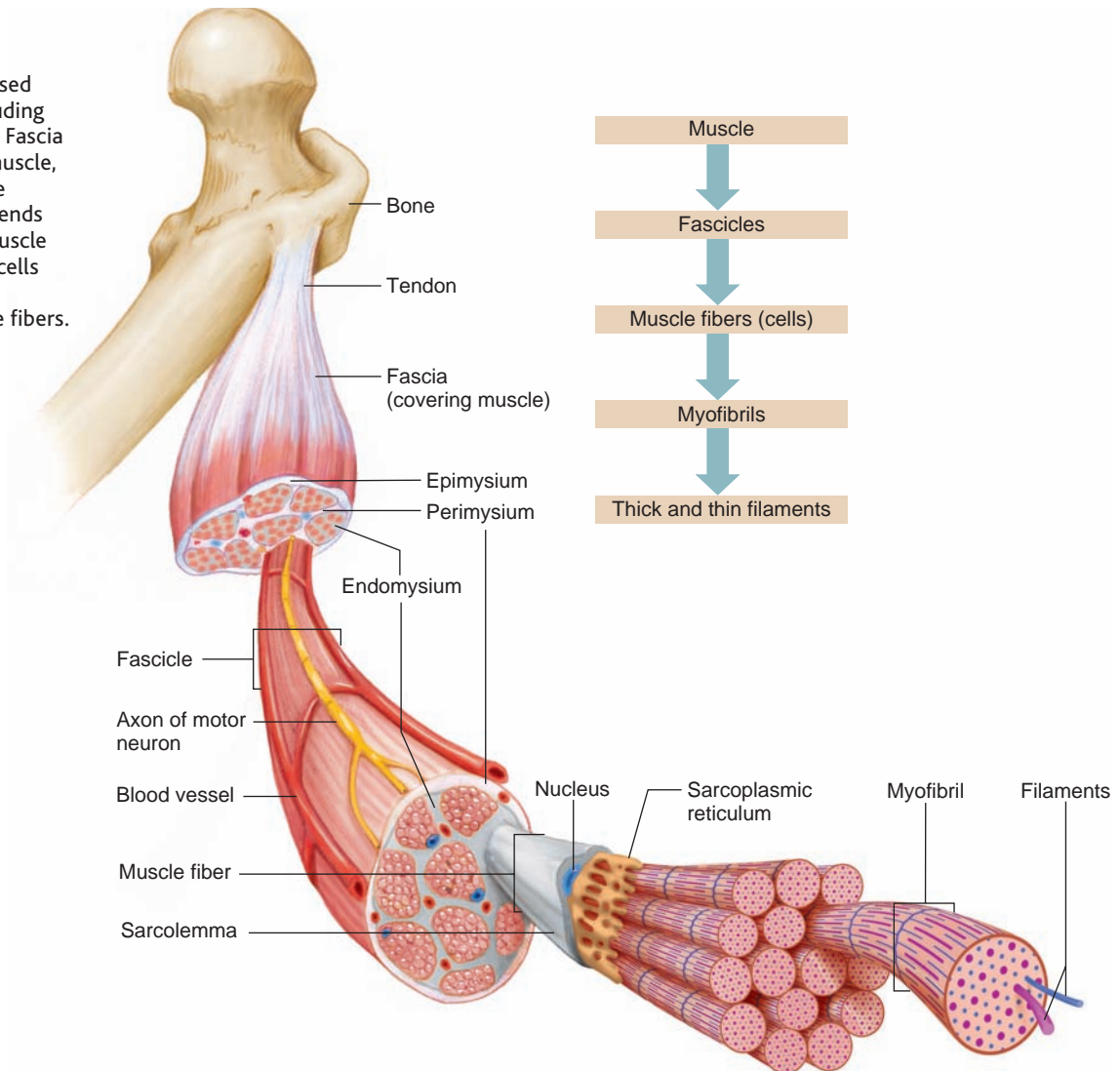
A skeletal muscle fiber is a single cell that contracts in response to stimulation and then relaxes when the stimulation ends. Each skeletal muscle fiber is a thin, elongated cylinder with rounded ends, and it may extend the full length of the muscle. Just beneath its cell membrane (or *sarcolemma*), the cytoplasm (or *sarcoplasm*) of the fiber has many small, oval nuclei and mitochondria (fig. 8.1). The sarcoplasm also contains many threadlike **myofibrils** (mi'o-fi'brilz) that lie parallel to one another.

Myofibrils play a fundamental role in muscle contraction. They consist of two kinds of protein filaments—thick ones composed of the protein **myosin** (mi'o-sin) and thin ones mainly composed of the protein **actin** (ak'tin) (figs. 8.2 and 8.3). (Two other thin filament proteins, troponin and tropomyosin, are discussed later on page 181.) The organization of these filaments produces the characteristic alternating light and dark *striations*, or bands, of a skeletal muscle fiber.

The striations form a repeating pattern of units called **sarcomeres** (sar'ko-mēr-z) along each muscle fiber. The myofibrils may be thought of as sarcomeres joined end-to-end (fig. 8.2). Muscle fibers, and in a way muscles themselves, may be considered a collection of sarcomeres. Sarcomeres are discussed later as the functional units of muscle contraction (p. 181).

### Figure 8.1

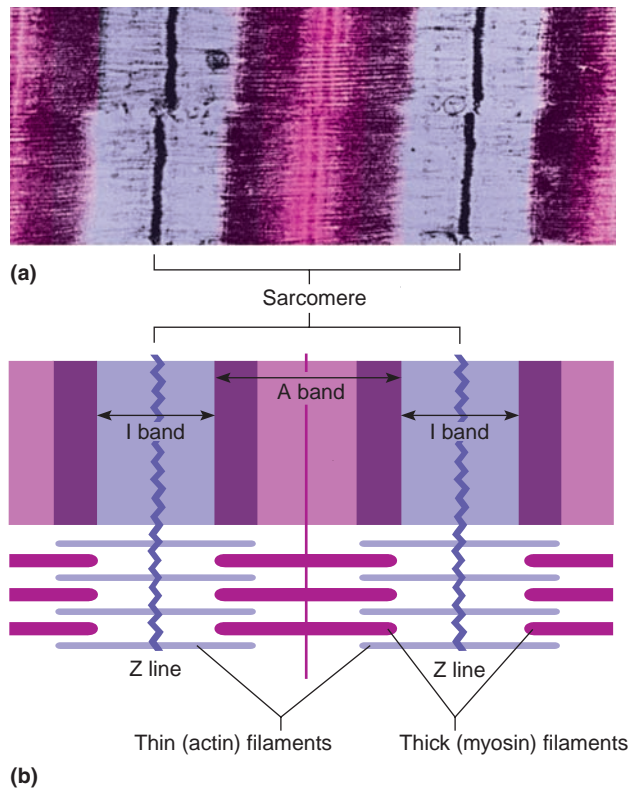
A skeletal muscle is composed of a variety of tissues, including layers of connective tissue. Fascia covers the surface of the muscle, epimysium lies beneath the fascia, and perimysium extends into the structure of the muscle where it separates muscle cells into fascicles. Endomysium separates individual muscle fibers.



### Figure 8.2

Skeletal muscle fiber. (a) A skeletal muscle fiber contains many myofibrils, each consisting of (b) repeating units called sarcomeres. The characteristic striations of a sarcomere reflect the organization of actin and myosin filaments.





**Figure 8.3**

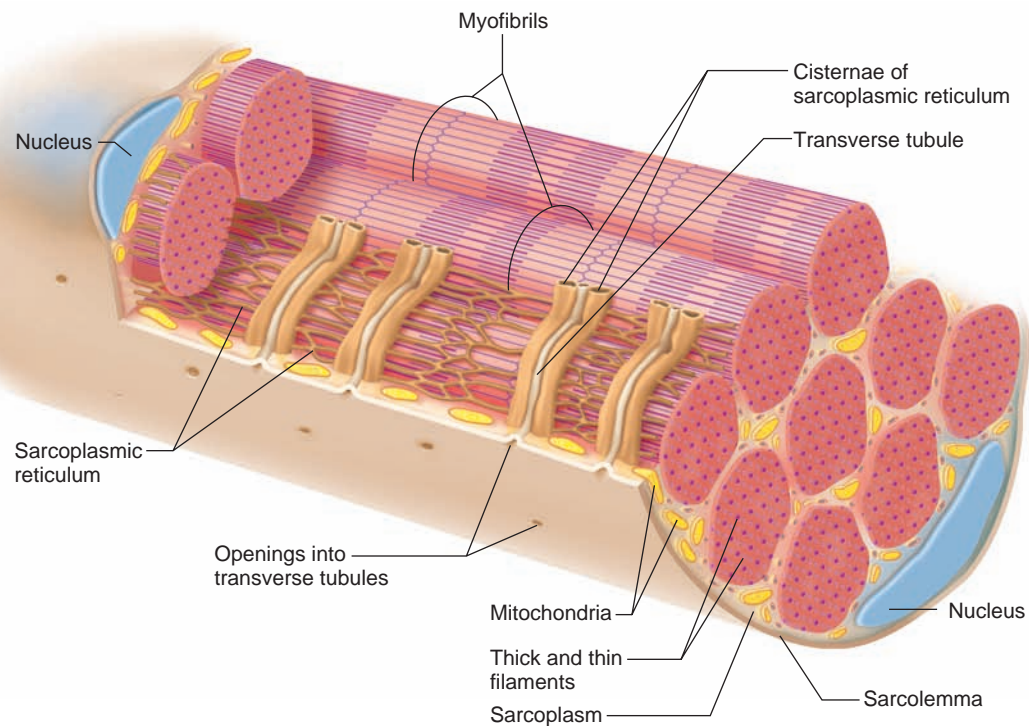
A sarcomere is a functional unit of muscle contraction. (a) Micrograph (16,000 $\times$ ). (b) The spatial relationship of thin and thick filaments in a sarcomere makes contraction possible.

Muscle cells are packed with actin and myosin, but several other types of protein are important in muscle function too. Discovery of the gene that causes the two most common forms of muscular dystrophy took many years because the protein that is absent or incomplete, called dystrophin, comprises only 0.002% of the protein in skeletal muscle. (see Genetics Connection on page 191.)

The striation pattern of skeletal muscle fibers has two main parts. The first, the *I bands* (the light bands), are composed of thin actin filaments directly attached to structures called *Z lines*.

The second part of the striation pattern consists of the *A bands* (the dark bands), which are composed of thick myosin filaments overlapping thin actin filaments. The A band consists of a region where the thick and thin filaments overlap, and a central region (*H zone*) consisting only of thick filaments, plus a thickening known as the *M line* (fig. 8.2). The M line consists of proteins that help hold the thick filaments in place. A sarcomere extends from one Z line to the next (figs. 8.2 and 8.3).

Within the sarcoplasm of a muscle fiber is a network of membranous channels that surrounds each myofibril and runs parallel to it (fig. 8.4). These membranes form the **sarcoplasmic reticulum**, which corresponds to the endoplasmic reticulum of other cells.



**Figure 8.4**

Within the sarcoplasm of a skeletal muscle fiber are a network of sarcoplasmic reticulum and a system of transverse tubules.

Another set of membranous channels, called **transverse tubules** (T tubules), extends inward as invaginations from the fiber's membrane and passes all the way through the fiber. Thus, each tubule opens to the outside of the muscle fiber and contains extracellular fluid. Furthermore, each transverse tubule lies between two enlarged portions of the sarcoplasmic reticulum called *cisternae*, near the region where the actin and myosin filaments overlap. The sarcoplasmic reticulum and transverse tubules activate the muscle contraction mechanism when the fiber is stimulated.

Muscle fibers and their associated connective tissues are flexible but can tear if overstretched. This type of injury, common in athletes, is called *muscle strain*. The seriousness of the injury depends on the degree of damage the tissues sustain. If the strain is mild, only a few muscle fibers are injured, the fascia remains intact, and loss of function is minimal. In a severe strain, however, many muscle fibers as well as the fascia tear, and muscle function may be completely lost. Such a severe strain is painful and produces discoloration and swelling.

### Check Your Recall

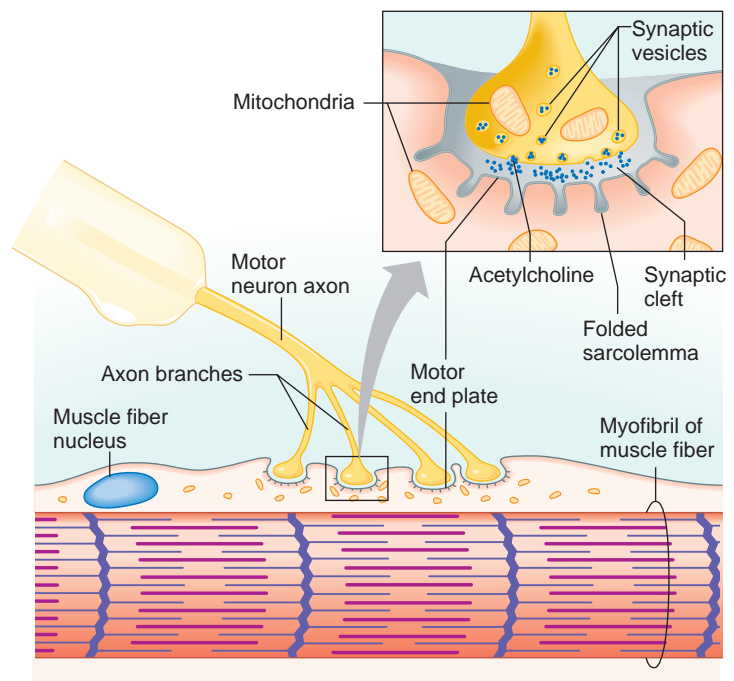
1. Describe how connective tissue is part of a skeletal muscle.
2. Describe the general structure of a skeletal muscle fiber.
3. Explain why skeletal muscle fibers appear striated.
4. Explain the relationship between the sarcoplasmic reticulum and the transverse tubules.

## Neuromuscular Junction

Recall from chapter 5 (p. 111) that neurons (nerve cells) play a role in body communication by conducting nerve impulses. Neurons that control effectors, including skeletal muscle, are called **motor neurons**.

Each skeletal muscle fiber is functionally (but not physically) connected to the axon of a motor neuron that passes outward from the brain or the spinal cord, in much the same way that you can talk into a cell phone although your mouth is not in direct physical contact with it. This functional connection is called a **synapse** (sin'aps). Neurons communicate with the cells that they control by releasing chemicals, called **neurotransmitters** (nu'ro-trans'mit-erz), at synapses. Normally, a skeletal muscle fiber contracts only upon stimulation by a motor neuron.

The connection between the motor neuron and the muscle fiber is called a **neuromuscular junction**. Here, the muscle fiber membrane is specialized to form a **motor end plate**. In this region of the muscle fiber, nuclei and mitochondria are abundant, and the cell membrane (sarcolemma) is extensively folded (fig. 8.5).



**Figure 8.5**

A neuromuscular junction includes the end of a motor neuron and the motor end plate of a muscle fiber.

The end of the motor neuron branches and projects into recesses of the muscle fiber membrane. The cytoplasm at the distal ends of these motor neuron axons is rich in mitochondria and contains many tiny vesicles (synaptic vesicles) that store neurotransmitters.

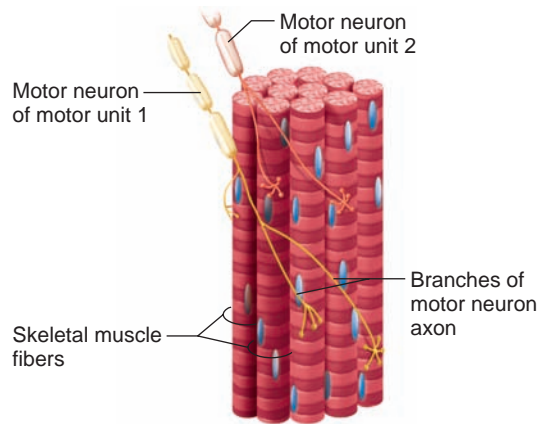
When a nerve impulse traveling from the brain or spinal cord reaches the end of a motor neuron axon, some of the vesicles release neurotransmitter molecules into the gap (synaptic cleft) between the neuron and the motor end plate of the muscle fiber. This action stimulates the muscle fiber to contract.

## Motor Units

A muscle fiber usually has a single motor end plate. The axons of motor neurons, however, are densely branched. By means of these branches, one motor neuron may connect to many muscle fibers. When a motor neuron transmits an impulse, all of the muscle fibers it links to are stimulated to contract simultaneously. Together, a motor neuron and the muscle fibers that it controls constitute a **motor unit** (mo'tor u'nit) (fig. 8.6).

### Check Your Recall

5. Which two structures approach each other at a neuromuscular junction?
6. Describe a motor end plate.
7. What is the function of a neurotransmitter?
8. What is a motor unit?



**Figure 8.6**

Two motor units. Muscle fibers within a motor unit are innervated by a single neuron and may be distributed throughout the muscle.

## 8.3 SKELETAL MUSCLE CONTRACTION

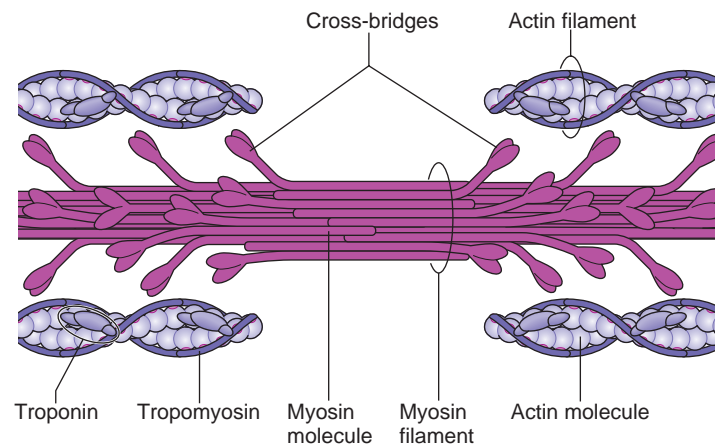
A muscle fiber contraction is a complex interaction of organelles and molecules in which myosin binds to actin and exerts a pulling action. The result is a movement within the myofibrils in which the filaments of actin and myosin slide past one another. This action shortens the muscle fiber so that it pulls on its attachments.

### Role of Myosin and Actin

A myosin molecule is composed of two twisted protein strands with globular parts called cross-bridges projecting outward along their lengths. Many of these molecules comprise a myosin (thick) filament (fig. 8.7). An actin molecule is a globular structure with a binding site to which the myosin cross-bridges can attach. Many actin molecules twist into a double strand (helix), forming an actin (thin) filament. The proteins **troponin** and **tropomyosin** are also part of the actin filament (fig. 8.7).

The sarcomere is considered the functional unit of skeletal muscles because the contraction of an entire skeletal muscle can be described in terms of the shortening of sarcomeres within its muscle fibers. The force that shortens the sarcomeres comes from the cross-bridges pulling on the thin filaments. A myosin cross-bridge can attach to an actin binding site and bend slightly, pulling on the actin filament. Then the head can release, straighten, combine with another binding site further down the actin filament, and pull again (fig. 8.8).

The **sliding filament model** includes all of these events and gets its name from the way the sarcomeres shorten. Thick and thin filaments do not change length. Rather, they slide past one another, with the thin filaments sliding toward the center of the sarcomere from both ends (fig. 8.9).



**Figure 8.7**

Thick filaments are composed of the protein myosin, and thin filaments are composed primarily of the protein actin. Myosin molecules have cross-bridges that extend toward nearby actin filaments.

The globular portions of the myosin filaments contain an enzyme, **ATPase**, which catalyzes the breakdown of ATP to ADP and phosphate. The reaction releases energy that puts the myosin cross-bridge in a “cocked” position (see chapter 4, p. 80). When a cocked cross-bridge binds to actin, it pulls on the thin filament. After the cross-bridge pulls, another ATP binding to the cross-bridge causes it to be released from actin even before the ATP splits. This cycle repeats as long as ATP is available as an energy source and as long as the muscle fiber is stimulated to contract.

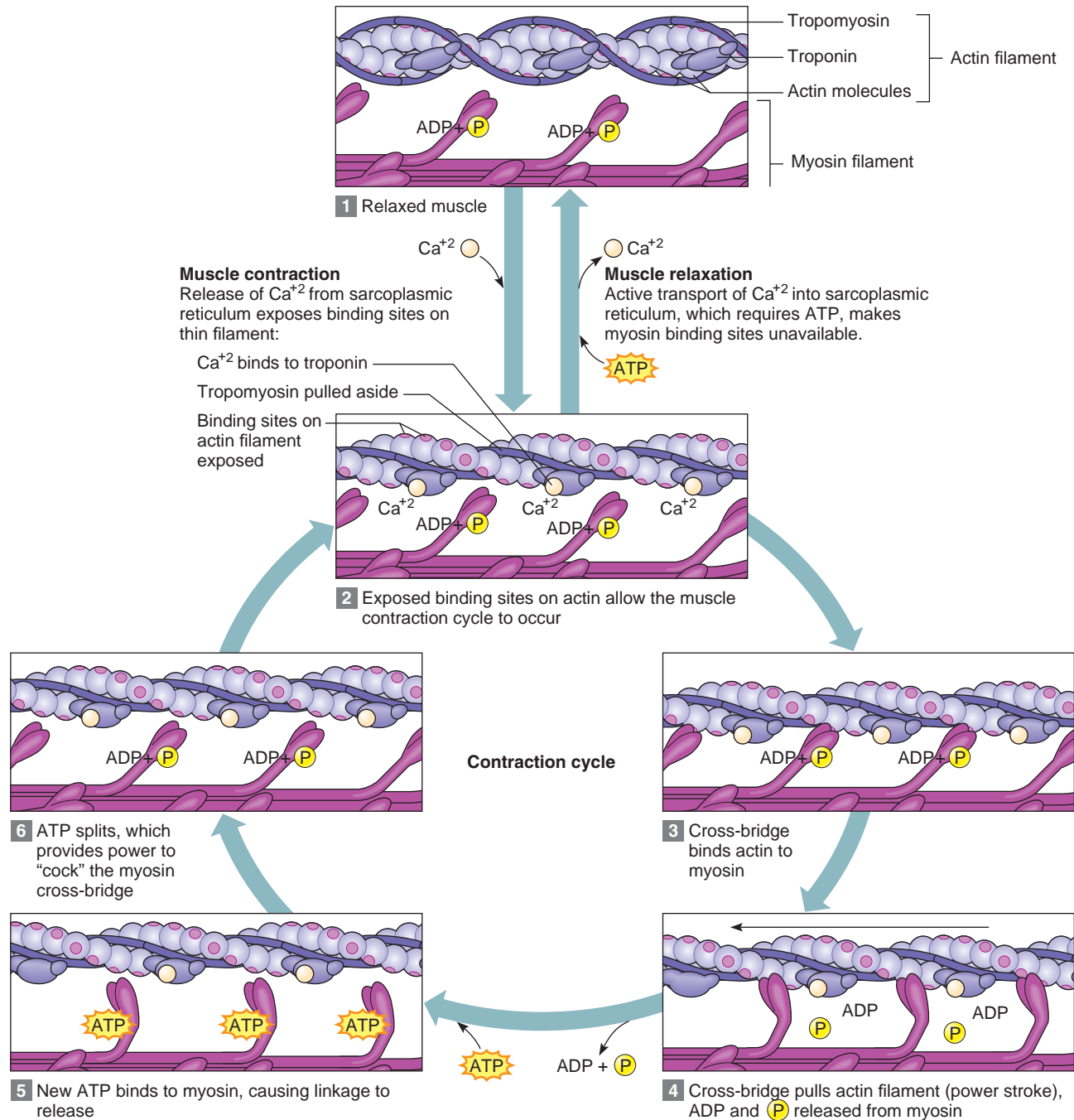
### Stimulus for Contraction

A skeletal muscle fiber normally does not contract until a neurotransmitter stimulates it. The neurotransmitter in this case is **acetylcholine** (as’ē-til-ko’lēn). This neurotransmitter is synthesized in the cytoplasm of the motor neuron and stored in vesicles at the distal end of the motor neuron axons. When a nerve impulse (described in chapter 9, p. 224) reaches the end of a motor neuron axon, some of the vesicles release their acetylcholine into the space (synaptic cleft) between the motor neuron axon and the motor end plate (see fig. 8.5).

Acetylcholine diffuses rapidly across the synaptic cleft and binds to specific protein molecules (receptors) in the muscle fiber membrane, increasing membrane permeability to sodium ions. Entry of these charged particles into the muscle cell stimulates a **muscle impulse** (mus’el im’puls), which is very much like a nerve impulse. The impulse passes in all directions over the surface of the muscle fiber membrane and travels through the transverse tubules, deep into the fiber, until it reaches the sarcoplasmic reticulum (see fig. 8.4).

The sarcoplasmic reticulum contains a high concentration of calcium ions. In response to a muscle impulse,





**Figure 8.8**

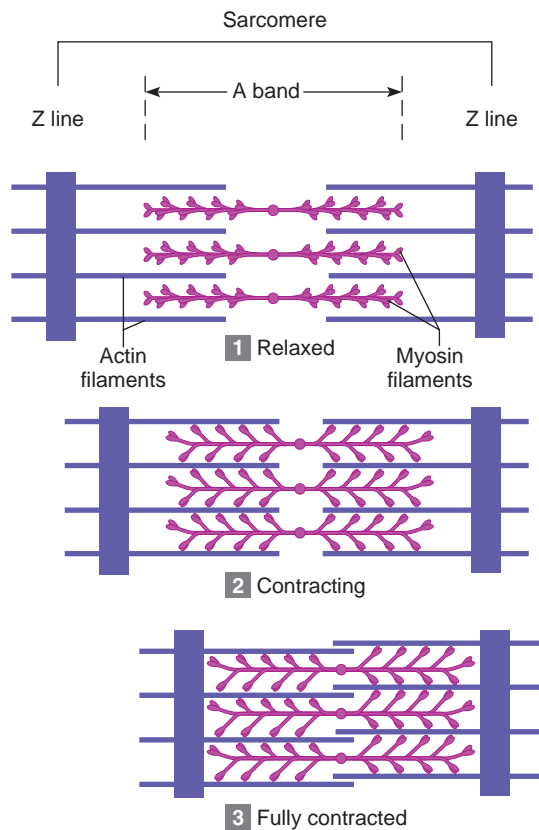
The sliding filament model. (1) and (2) When calcium ion concentration rises, binding sites on actin filaments open, and cross-bridges attach. (3) and (4) Upon binding to actin, cross-bridges spring from the cocked position and pull on actin filaments. (5) ATP binds to the cross-bridge (but is not yet broken down), causing the cross-bridge to release from the actin filament. (6) ATP breakdown provides energy to "cock" the unattached myosin cross-bridge. As long as ATP and calcium ions are present, the cycle continues. When calcium ion concentration is low, the muscle remains relaxed.

the membranes of the cisternae become more permeable to these ions, and the calcium ions diffuse into the sarcoplasm of the muscle fiber.


When a high concentration of calcium ions is in the sarcoplasm, troponin and tropomyosin interact in a way that exposes binding sites on actin. As a result, linkages

form between the actin and myosin filaments, and the muscle fiber contracts (see figs. 8.8 and 8.9). The contraction, which also requires ATP, continues as long as nerve impulses release acetylcholine.

When the nerve impulses cease, two events lead to muscle relaxation. First, the acetylcholine that stimulated



(a)



(b)

### Figure 8.9

When a skeletal muscle contracts, (a) individual sarcomeres shorten as thick and thin filaments slide past one another. (b) This transmission electron micrograph shows a sarcomere shortening during muscle contraction (23,000 $\times$ ).

the muscle fiber is rapidly decomposed by the enzyme **acetylcholinesterase** (as'ĕ-til-ko''lin-es'ter-ās). This enzyme is present at the neuromuscular junction on the membranes of the motor end plate. Acetylcholinesterase prevents a single nerve impulse from continuously stimulating the muscle fiber.

The second event in relaxation occurs once acetylcholine is broken down and the stimulus to the muscle fiber ceases. Calcium ions are actively transported back into the sarcoplasmic reticulum, which decreases the calcium ion concentration of the sarcoplasm. The linkages between actin and myosin filaments break, and consequently, the muscle fiber relaxes. Table 8.1 summarizes the major events leading to muscle contraction and relaxation.

The bacterium *Clostridium botulinum* produces a poison, called botulinum toxin, that can prevent the release of acetylcholine from motor neuron axons at neuromuscular junctions, causing *botulism*, a very serious form of food poisoning. Most cases of botulism are caused by eating home-processed food that has not been heated enough to kill the bacteria in it or to inactivate the toxin.

Botulinum toxin blocks stimulation of muscle fibers, paralyzing muscles, including those responsible for breathing. Without prompt medical treatment, the fatality rate for botulism is high. Very small amounts of botulinum toxin ("botox") are injected into facial skin to temporarily smooth wrinkles by preventing local muscles from contracting. If done to excess, botox can cause the face to appear frozen.

### Check Your Recall

9. Explain how a motor nerve impulse can trigger a muscle contraction.
10. Explain how the filaments of a myofibril interact during muscle contraction.

## Energy Sources for Contraction

ATP molecules supply the energy for muscle fiber contraction. However, a muscle fiber has only enough ATP to enable it to contract for a very short time, so when a fiber is active, ATP must be regenerated.

The initial source of energy available to a contracting muscle comes from existing ATP molecules in the cell. Almost immediately, however, cells must regenerate ATP from ADP and phosphate. The molecule that makes this possible is **creatine phosphate** (kre'ah-tin fos'fāt). Like ATP, creatine phosphate contains high-energy phosphate bonds, and it is four to six times more abundant in muscle fibers than ATP. Creatine



**Table 8.1****Major Events of Muscle Contraction and Relaxation****Muscle Fiber Contraction**

1. A nerve impulse travels down a motor neuron axon.
2. The motor neuron terminal releases the neurotransmitter acetylcholine (ACh).
3. ACh binds to ACh receptors.
4. The sarcolemma is stimulated, and a muscle impulse travels over the surface of the muscle fiber and deep into the fiber through the transverse tubules.
5. The muscle impulse reaches the sarcoplasmic reticulum and calcium channels open.
6. Calcium ions diffuse from the sarcoplasmic reticulum into the sarcoplasm and bind to troponin molecules.
7. Tropomyosin molecules move and expose specific sites on actin.
8. Actin and myosin form linkages.
9. Thin (actin) filaments are pulled toward the center of the sarcomere by myosin cross-bridges.
10. The muscle fiber shortens as a contraction occurs.

**Muscle Fiber Relaxation**

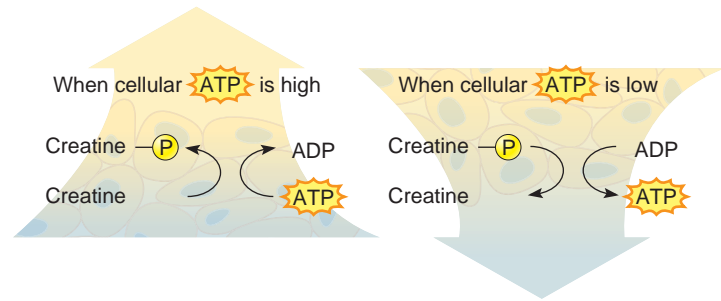
1. Acetylcholinesterase decomposes acetylcholine, and the muscle fiber membrane is no longer stimulated.
2. Calcium ions are actively transported into the sarcoplasmic reticulum.
3. ATP breaks linkages between actin and myosin filaments without breakdown of the ATP itself.
4. Breakdown of ATP “cocks” the cross-bridges
5. Troponin and tropomyosin molecules inhibit the interaction between myosin and actin filaments.
6. The muscle fiber remains relaxed, yet ready, until stimulated again.

phosphate, however, cannot directly supply energy to a cell's energy-utilizing reactions. Instead, it stores excess energy released from the mitochondria. When ATP supply is sufficient, an enzyme in the mitochondria (creatine phosphokinase) catalyzes the synthesis of creatine phosphate, which stores excess energy in its phosphate bonds (fig. 8.10).

As ATP decomposes, the energy from creatine phosphate can be transferred to ADP molecules, converting them back into ATP. Active muscle, however, rapidly exhausts the supply of creatine phosphate. When this happens, the muscle fibers use cellular respiration of glucose as an energy source for synthesizing ATP.

## Oxygen Supply and Cellular Respiration

As chapter 4 describes (p. 82), glycolysis can take place in the absence of oxygen. However, the more complete breakdown of glucose occurs in the mitochondria and requires oxygen. The blood carries the oxygen required

**Figure 8.10**

Creatine phosphate may be used to replenish ATP stores when ATP levels in a muscle cell are low.

to support this aerobic respiration from the lungs to body cells. Red blood cells carry the oxygen, loosely bound to molecules of **hemoglobin**, the pigment responsible for the red color of blood.

Another pigment, **myoglobin**, is synthesized in muscle cells and imparts the reddish-brown color of skeletal muscle tissue. Like hemoglobin, myoglobin can combine loosely with oxygen. This ability to temporarily store oxygen reduces a muscle's requirement for a continuous blood supply during muscular contraction (fig. 8.11).

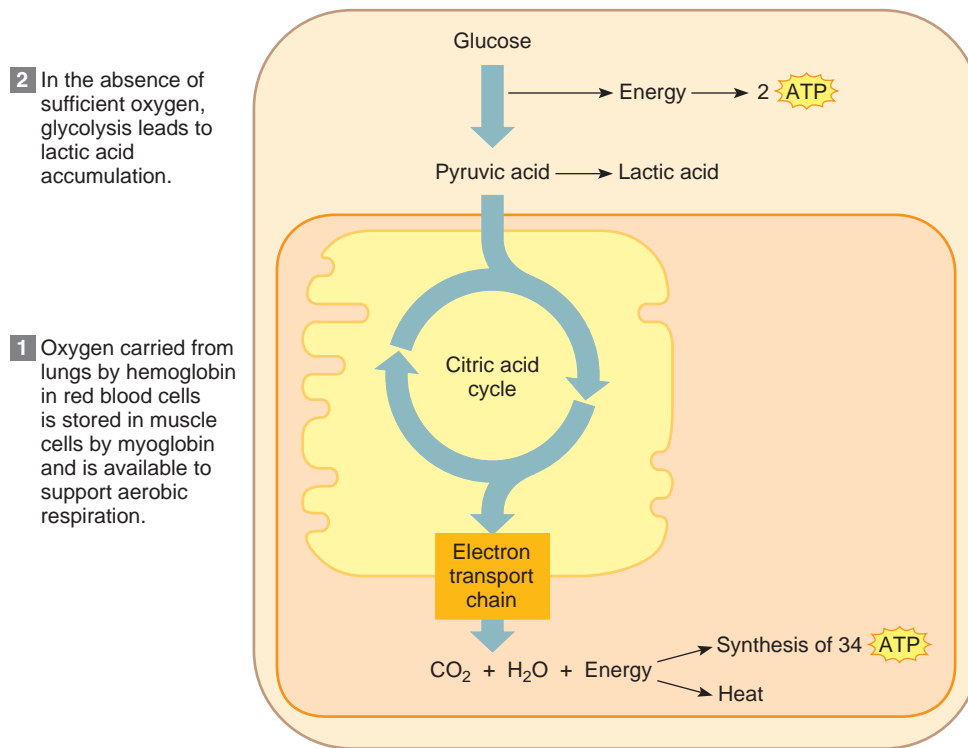
## Oxygen Debt

When a person is resting or is moderately active, the respiratory and cardiovascular systems can usually supply sufficient oxygen to skeletal muscles to support aerobic respiration. However, this is not the case when skeletal muscles are used strenuously for even a minute or two. In this situation, muscle fibers must increasingly use anaerobic respiration to obtain energy.

In one form of anaerobic respiration, glucose molecules are broken down by glycolysis to yield *pyruvic acid* (see chapter 4, p. 82). Because the oxygen supply is low, however, the pyruvic acid reacts to produce *lactic acid*, which may accumulate in the muscles (fig. 8.11). Lactic acid diffuses into the bloodstream and eventually reaches the liver. In liver cells, reactions requiring ATP synthesize glucose from lactic acid.

During strenuous exercise, available oxygen is used primarily to synthesize the ATP the muscle fiber requires to contract, rather than to make ATP for synthesizing glucose from lactic acid. Consequently, as lactic acid accumulates, a person develops an **oxygen debt** (ok'si-jen det) that must be repaid. Oxygen debt equals the amount of oxygen liver cells require to convert the accumulated lactic acid into glucose, plus the amount muscle cells require to restore ATP and creatine phosphate to their original concentrations.

The conversion of lactic acid back into glucose is slow. Repaying an oxygen debt following vigorous exercise may take several hours.

**Figure 8.11**

The oxygen required to support aerobic respiration is carried in the blood and stored in myoglobin. In the absence of sufficient oxygen, pyruvic acid is converted to lactic acid by anaerobic respiration. The maximum number of ATPs generated per glucose molecule varies with cell type; in skeletal muscle, it is 36 (2 + 34).

The metabolic capacity of a muscle may change with training. With high-intensity exercise that depends more on glycolysis for ATP, a muscle synthesizes more glycolytic enzymes, and its capacity for glycolysis increases. With aerobic exercise, more capillaries and mitochondria form, and the muscle's capacity for aerobic respiration is greater. Table 8.2 summarizes muscle metabolism, and the Topic of Interest on page 186 discusses the dangerous use of steroid drugs to enhance muscle performance.

## Muscle Fatigue

A muscle exercised strenuously for a prolonged period may lose its ability to contract, a condition called

*fatigue*. Interruption in the muscle's blood supply or, rarely, lack of acetylcholine in motor neuron axons may cause fatigue. However, fatigue is most likely to arise from accumulation of lactic acid in the muscle as a result of anaerobic respiration. The lactic acid buildup lowers pH, and as a result, muscle fibers no longer respond to stimulation.

Occasionally, a muscle becomes fatigued and cramps at the same time. A cramp is a painful condition in which a muscle undergoes a sustained involuntary contraction. Cramps are thought to occur when changes in the extracellular fluid surrounding the muscle fibers and their motor neurons somehow trigger uncontrolled stimulation of the muscle.

Table 8.2		Muscle Metabolism
<i>Type of Exercise</i>	Low to moderate intensity: Blood flow provides sufficient oxygen for cellular requirements	High intensity: Oxygen supply is not sufficient for cellular requirement
<i>Pathway Used</i>	Glycolysis, leading to pyruvic acid formation and aerobic respiration	Glycolysis, leading to lactic acid formation
<i>ATP Production</i>	36 ATP per glucose for skeletal muscle	2 ATP per glucose
<i>Waste Product</i>	Carbon dioxide is exhaled	Lactic acid accumulates

## Topic of Interest



## Steroids and Athletes—An Unhealthy Combination

In the 1988 summer Olympics held in Seoul, South Korea, Canadian Ben Johnson flew past his competitors in the 100-meter run. But seventy-two hours later, officials rescinded the gold medal he won for his record-smashing time of 9.79 seconds, after a urine test revealed traces of the drug stanozolol, a synthetic stand-in for the steroid hormone testosterone (fig. 8A). Johnson's natural testosterone level was only 15% of normal—evidence of negative feedback acting because of an outside supply of the



**Figure 8A**

Canadian track star Ben Johnson ran away with the gold medal in the 100-meter race at the 1988 Summer Olympics—but then had to return the award when traces of a steroid drug showed up in his urine. Drug abuse continues to be a problem among amateur as well as professional athletes.

hormone. Steroid abuse among athletes, both amateur and professional, continues today, and among high school and college athletes is on the increase, according to the American College of Sports Medicine.

Athletes who abuse steroids do so to take advantage of the hormone's ability to increase muscular strength. But improved performance today may have consequences tomorrow. Steroids hasten adulthood, stunting height and causing early hair loss. In males, excess steroid hormones lead to breast development, and in females to a deepened voice, hairiness, and a male physique. The kidneys, liver, and heart may be damaged, and atherosclerosis may develop because steroids raise LDL and lower HDL—the opposite of a healthy cholesterol profile. In males, the body mistakes the synthetic steroids for the natural hormone and lowers its own production of testosterone—as Ben Johnson found out. Infertility may result. Steroids can also cause psychiatric symptoms, including delusions, depression, and violence.

Steroid abuse began in Nazi Germany, where Hitler used the drugs to fashion his “super race.” Ironically, steroids were also used shortly after the war to build up the bodies of concentration camp survivors. In the 1950s, Soviet athletes began using steroids in the Olympics, and a decade later, U.S. athletes did the same. In 1976, the International Olympic Committee banned steroid use and required urine tests for detecting the drugs.

Anabolic steroids were created for medical purposes. They were first used clinically in the 1930s to treat underdevelopment of the testes and the resulting deficit in testosterone. In the 1950s, physicians used anabolic steroids to treat anemia and muscle-wasting disorders, and to bulk up patients whose muscles had atrophied due to extended bed rest. In the 1960s, anabolic steroids were used to treat some forms of short stature and dwarfism, a practice that was discontinued when pure preparations of human growth hormone became available through recombinant DNA technology. Today, anabolic steroids are used to treat wasting associated with AIDS.

Several hours after death, the skeletal muscles undergo a partial contraction that fixes the joints. This condition, *rigor mortis*, may continue for 72 hours or more. It results from an increase in membrane permeability to calcium ions and a decrease in ATP in muscle fibers, which prevents relaxation. Thus, the actin and myosin filaments of the muscle fibers remain linked until the muscles begin to decompose.

## Heat Production

Less than half of the energy released in cellular respiration is available for use in metabolic processes; the rest becomes heat. Although all active cells generate heat, muscle tissue is a major heat source because muscle is such a large proportion of the total body mass. Blood transports heat generated in muscle to other tissues, which helps maintain body temperature.



### Check Your Recall

11. Which biochemicals provide the energy to regenerate ATP?
12. What are the sources of oxygen for aerobic respiration?
13. How are lactic acid, oxygen debt, and muscle fatigue related?
14. What is the relationship between cellular respiration and heat production?

## 8.4 MUSCULAR RESPONSES

One way to observe muscle contraction is to remove a single muscle fiber from a skeletal muscle and connect it to a device that records changes in the fiber's length. Such experiments usually require an electrical device that can produce stimuli of varying strengths and frequencies.

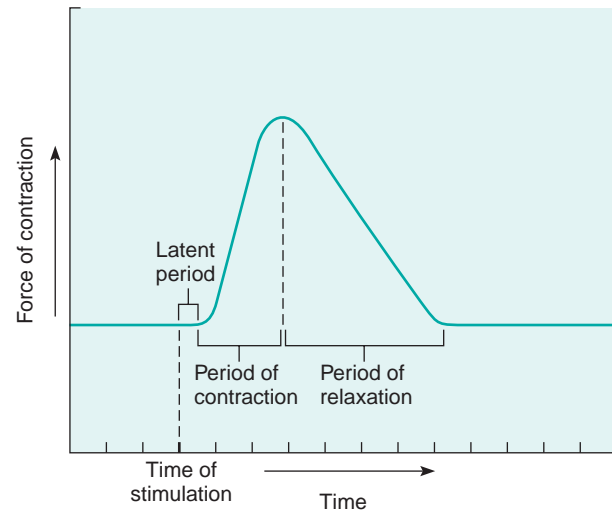
### Threshold Stimulus

When an isolated muscle fiber is exposed to a series of stimuli of increasing strength, the fiber remains unresponsive until a certain strength of stimulation called the **threshold stimulus** (thresh'old stim'u-lus) is applied. Once threshold is reached, an action potential is generated, resulting in a muscle impulse that spreads throughout the muscle fiber, releasing enough calcium ions from the sarcoplasmic reticulum to activate cross-bridge binding and contract that fiber. A single nerve impulse in a motor neuron normally releases enough ACh to bring the muscle fibers in its motor unit to threshold, generating a muscle impulse in each muscle fiber.

### Recording of a Muscle Contraction

The contractile response of a single muscle fiber to a muscle impulse is called a **twitch**. A twitch consists of a period of contraction, during which the fiber pulls at its attachments, followed by a period of relaxation, during which the pulling force declines. These events can be recorded in a pattern called a myogram (fig. 8.12). Note that a twitch has a brief delay between the time of stimulation and the beginning of contraction. This is the **latent period**, which in human muscle may be less than 2 milliseconds.

When a muscle fiber is brought to threshold under a given set of conditions, it tends to contract completely, such that each twitch generates the same force. This has been referred to as an *all-or-none* response. This is misleading, however, because in normal use of muscles, the force generated by muscle fibers and by whole muscles must vary.



**Figure 8.12**

A myogram of a single muscle twitch.

Understanding the contraction of individual muscle fibers is important for understanding how muscles work, but such contractions by themselves are of little significance in day-to-day activities. Rather, the actions we need to perform usually require the contraction of multiple muscle fibers simultaneously. To record how a whole muscle responds to stimulation, a skeletal muscle can be removed from a frog or other small animal and mounted on a special device. The muscle is then stimulated electrically, and when it contracts, it pulls on a lever. The lever's movement is recorded as a myogram. Because the myogram results from the combined twitches of muscle fibers taking part in the contraction, it looks essentially the same as the twitch contraction depicted in figure 8.12. The Topic of Interest on page 188 describes two types of twitches—the fatigue-resistant slow twitch and the fatigable fast twitch. Muscle fibers are either slow twitch or fast twitch.

The skeletal muscles of an average person have about half fast twitch and half slow twitch muscle fibers. In contrast, the muscles of an Olympic sprinter typically have more than 80% fast twitch muscle fibers, and those of an Olympic marathoner, more than 90% slow twitch muscle fibers.

Contractions of whole muscles enable us to perform everyday activities, but the force generated by those contractions must be controlled. For example, holding a styrofoam cup of coffee firmly enough that it does not slip through our fingers, but not so forcefully as to crush it, requires precise control of contractile force. In the whole muscle, the degree of tension developed reflects (1) the frequency at which individual muscle fibers are stimulated and (2) how many fibers take part in the overall contraction of the muscle.

## Topic of Interest



## Use and Disuse of Skeletal Muscles

Skeletal muscles are very responsive to use and disuse. Forcefully exercised muscles enlarge, which is called *muscular hypertrophy*. Conversely, an unused muscle undergoes *atrophy*, decreasing in size and strength.

The way a muscle responds to use also depends on the type of exercise. A muscle contracting with lower intensity, during swimming or running, activates *slow-twitch fibers*, which are oxidative and thus fatigue-resistant. With use, these specialized muscle fibers develop more mitochondria, and more extensive capillary networks envelop them. Such changes increase the slow-twitch fibers' ability to resist fatigue during prolonged exercise, although their sizes and strengths may remain unchanged.

Forceful exercise, such as weight lifting, in which a muscle exerts more than 75% of its maximum tension, utilizes *fast-twitch fibers*, which may be glycolytic and thus fatigable. In response to strenuous exercise, these fibers produce new filaments of actin and myosin, the diameters of the muscle fibers increase, and the entire muscle enlarges. However, the muscular hypertrophy does not produce new muscle fibers.

The strength of a muscular contraction is directly proportional to the diameter of the activated muscle fibers. Consequently, an enlarged muscle can produce stronger contractions than before. Such a change, however, does not increase the muscle's ability to resist fatigue during activities like swimming or running.

If regular exercise stops, the capillary networks shrink, and the number of mitochondria within the muscle fibers drops. The number of actin and myosin filaments decreases, and the entire muscle atrophies. Such atrophy commonly occurs when accidents or diseases interfere with motor nerve impulses and prevent them from reaching muscle fibers. An unused muscle may shrink to less than half its usual size within a few months.

The fibers of muscles whose motor neurons are severed not only shrink, but also may fragment and, in time, be replaced by fat or fibrous connective tissue. However, reinnervation within the first few months following an injury may restore muscle function.

## Summation

The force that a muscle fiber can generate is not limited to the maximum force of a single twitch. A muscle fiber exposed to a series of stimuli of increasing frequency reaches a point when it is unable to completely relax before the next stimulus in the series arrives. When this happens, the force of individual twitches combines by the process of **summation**. When the resulting forceful, sustained contraction lacks even partial relaxation, it is called a **tetanic** (tĕ-tan'ik) **contraction**, or tetanus (fig. 8.13).

## Recruitment of Motor Units

Anatomically, the muscle fibers within a muscle are organized into motor units, each of which is controlled by a single motor neuron. Each motor unit is also a functional unit, because a nerve impulse in its motor neuron will cause all of the fibers in that motor unit to contract at the same time. A whole muscle is composed of many motor units controlled by different motor neurons, which respond to different thresholds of stimulation. If only the motor neurons with low thresholds are stimulated, few motor units contract. At higher intensities of stimulation, other motor neurons respond, and more motor units are activated. Such an increase in the

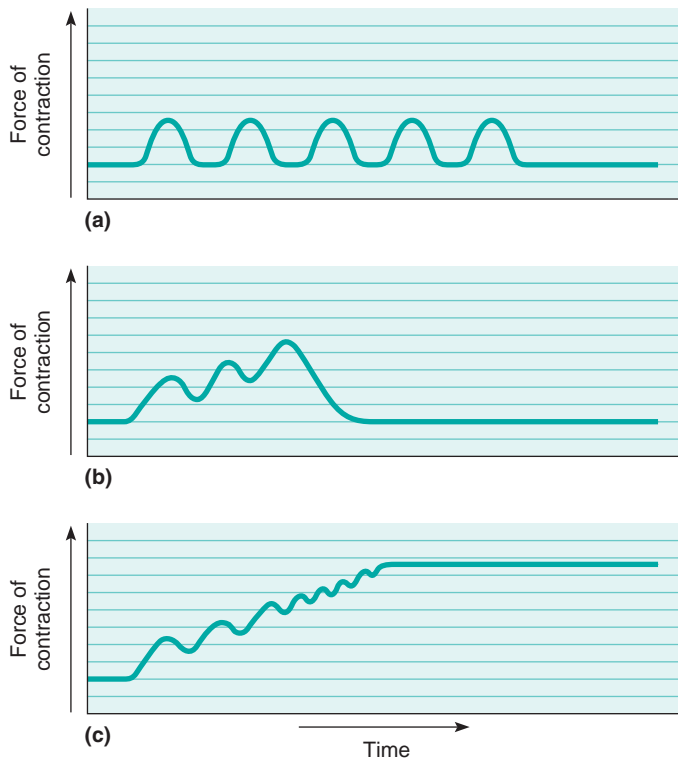
number of motor units being activated is called **recruitment** (re-krōōt'ment). As the intensity of stimulation increases, recruitment of motor units continues until, finally, all possible motor units in that muscle are activated and the muscle contracts with maximal tension.

## Sustained Contractions

At the same time twitches combine to increase force, the strength of the contractions may increase due to the recruitment of motor units. The smaller motor units, which have finer fibers, are most easily stimulated and tend to respond earlier in the series of stimuli. The larger motor units, which have thicker fibers, respond later and more forcefully. Summation and recruitment together can produce a *sustained contraction* of increasing strength.

Sustained contractions of whole muscles enable us to perform everyday activities. Such contractions are responses to a rapid series of impulses transmitted from the brain and spinal cord on motor neuron axons.

Even when a muscle appears to be at rest, its fibers undergo some sustained contraction. This is called **muscle tone** (tonus). Muscle tone is a response to nerve impulses that originate repeatedly from the spinal cord and stimulate a few muscle fibers. Muscle tone is particularly important in maintaining posture. If muscle tone



**Figure 8.13**

Myograms of (a) a series of twitches, (b) summation, and (c) a tetanic contraction. Note that stimulation frequency increases from one myogram to the next.

is suddenly lost, as happens when a person loses consciousness, the body collapses.

When skeletal muscles contract very forcefully, they may generate up to 50 pounds of pull for each square inch of muscle cross section. Consequently, large muscles, such as those in the thigh, can pull with several hundred pounds of force. Occasionally, this force is so great that the tendons of muscles tear away from their attachments to the bones (*muscle pull*).

### Check Your Recall

15. Define *threshold stimulus*.
16. What is recruitment?
17. Distinguish between a twitch and a sustained contraction.
18. How is muscle tone maintained?

## 8.5 SMOOTH MUSCLE

The contractile mechanism of smooth muscles is essentially the same as for skeletal muscles. The cells of smooth muscle, however, have some important structural and functional differences from the other types of muscle.

### Smooth Muscle Fibers

Recall from chapter 5 (p. 110) that smooth muscle cells are elongated, with tapering ends. They contain filaments of actin and myosin in myofibrils that extend the lengths of the cells. However, these filaments are organized differently and more randomly than those in skeletal muscle. Consequently, smooth muscle cells lack striations. The sarcoplasmic reticulum in these cells is not well developed.

The two major types of smooth muscles are multiunit and visceral. In **multiunit smooth muscle**, the muscle fibers are separate rather than organized into sheets. Smooth muscle of this type is found in the irises of the eyes and in the walls of blood vessels. Typically, multiunit smooth muscle tissue contracts only in response to stimulation by motor nerve impulses or certain hormones.

**Visceral smooth muscle** is composed of sheets of spindle-shaped cells in close contact with one another (see fig. 5.22, p. 111). This more common type of smooth muscle is found in the walls of hollow organs, such as the stomach, intestines, urinary bladder, and uterus.

Fibers of visceral smooth muscles can stimulate each other. When one fiber is stimulated, the impulse moving over its surface may excite adjacent fibers, which in turn stimulate still others. Visceral smooth muscles also display *rhythmicity*, a pattern of repeated contractions. Rhythmicity is due to self-exciting fibers that deliver spontaneous impulses periodically into surrounding muscle tissue. These two features—transmission of impulses from cell to cell and rhythmicity—are largely responsible for the wavelike motion, called **peristalsis**, that occurs in certain tubular organs, such as the intestines, and helps force the contents of these organs along their lengths.

### Smooth Muscle Contraction

Smooth muscle contraction resembles skeletal muscle contraction in a number of ways. Both mechanisms include reactions of actin and myosin, both are triggered by membrane impulses and an increase in intracellular calcium ions, and both use energy from ATP. However, these two types of muscle tissue also have significant differences.

Recall that acetylcholine is the neurotransmitter in skeletal muscle. Two neurotransmitters affect smooth muscle—acetylcholine and norepinephrine. Each of these neurotransmitters stimulates contractions in some smooth muscles and inhibits contractions in others (see chapter 9, p. 251). Also, a number of hormones affect smooth muscle, stimulating contractions in some cases and altering the degree of response to neurotransmitters in others.

Smooth muscle is slower to contract and to relax than skeletal muscle. On the other hand, smooth muscle



can maintain a forceful contraction longer with a given amount of ATP. Also, unlike skeletal muscle, smooth muscle fibers can change length without changing tautness; therefore, smooth muscles in the stomach and intestinal walls can stretch as these organs fill, yet maintain the pressure inside these organs.

### Check Your Recall

19. Describe two major types of smooth muscle.
20. What special characteristics of visceral smooth muscle make peristalsis possible?
21. How does smooth muscle contraction differ from that of skeletal muscle?

## 8.6 CARDIAC MUSCLE

Cardiac muscle is found only in the heart. Its mechanism of contraction is essentially the same as that of skeletal and smooth muscle, but with some important differences.

Cardiac muscle is composed of branching, striated cells interconnected in three-dimensional networks (see fig. 5.23, p. 112). Each cell has many filaments of actin and myosin, similar to those in skeletal muscle. A cardiac muscle cell also has a sarcoplasmic reticulum, many mitochondria, and a system of transverse tubules. However, the cisternae of cardiac muscle fibers are less well developed and store less calcium than those of skeletal muscle. On the other hand, the transverse tubules of cardiac muscle are larger, and they release many calcium ions into the sarcoplasm in response to muscle impulses. This extra calcium from the transverse tubules comes from the extracellular fluid and causes cardiac muscle twitches to be longer than skeletal muscle twitches.

The opposing ends of cardiac muscle cells are connected by crossbands called *intercalated discs*. These bands form from elaborate junctions between cell membranes. The discs help to join cells and to transmit the force of contraction from cell to cell. Intercalated discs also allow muscle impulses to pass freely so that they travel rapidly from cell to cell.

When one portion of the cardiac muscle network is stimulated, the resulting impulse passes to the other parts of the network, and the whole structure contracts as a functional unit. Cardiac muscle is also self-exciting and rhythmic. Consequently, a pattern of contraction and relaxation repeats again and again and causes the rhythmic contractions of the heart.

Table 8.3 summarizes the characteristics of the three types of muscle tissue. The Genetics Connection on page 191 considers several inherited diseases that affect the muscular system.

### Check Your Recall

22. How is cardiac muscle similar to smooth muscle?
23. How is cardiac muscle similar to skeletal muscle?
24. What is the function of intercalated discs?
25. What characteristic of cardiac muscle contracts the heart as a unit?

## 8.7 SKELETAL MUSCLE ACTIONS

Skeletal muscles provide a variety of body movements, as described in chapter 7 (pp. 165–166). Each muscle's movement depends largely on the kind of joint it is associated with and the way the muscle attaches on either side of that joint.

**Table 8.3** Types of Muscle Tissue

	Skeletal	Smooth	Cardiac
<i>Major Location</i>	Skeletal muscles	Walls of hollow viscera, blood vessels	Wall of the heart
<i>Major Function</i>	Movement of bones at joints, maintenance of posture	Movement of viscera, peristalsis, vasoconstriction	Pumping action of the heart
<i>Cellular Characteristics</i>			
Striations	Present	Absent	Present
Nucleus	Many nuclei	Single nucleus	Single nucleus
Special features	Well-developed transverse tubule system	Lacks transverse tubules	Well-developed transverse tubule system; intercalated discs separating adjacent cells
<i>Mode of Control</i>	Voluntary	Involuntary	Involuntary
<i>Contraction Characteristics</i>	Contracts and relaxes rapidly	Contracts and relaxes slowly; self-exciting; rhythmic	Network of cells contracts as a unit; self-exciting; rhythmic

## Genetics Connection



## Inherited Diseases of Muscle

A variety of inherited conditions affect muscle tissue. These disorders differ in the nature of the genetic defect, the type of protein that is abnormal in form or function, and the particular muscles in the body that are impaired.

### The Muscular Dystrophies—Missing Proteins

A muscle cell is packed with filaments of actin and myosin. Less abundant, but no less important, is a protein called *dystrophin*. It holds skeletal muscle cells together by linking actin in the cell to glycoproteins (called *dystrophin-associated glycoproteins*, or DAGs) that are part of the cell membrane. This helps attach the cell to the surrounding extracellular matrix. Missing or abnormal dystrophin or DAGs cause muscular dystrophies. These illnesses vary in severity and age of onset, but in all cases, muscles weaken and degenerate. Eventually, fat and connective tissue replace muscle.

Duchenne muscular dystrophy (DMD) is the most severe type of the illness (fig. 8B). Symptoms begin by age five and affect only boys. By age thirteen, the person cannot walk, and by early adulthood he usually dies from failure of the respira-



**Figure 8B**

This young man has Duchenne muscular dystrophy. The condition has not yet severely limited his activities, but he shows the hypertrophied (overdeveloped) calf muscles that result from his inability to rise from a sitting position the usual way—an early sign of the illness.

tory muscles. In DMD, dystrophin is often missing. In Becker muscular dystrophy, symptoms begin in early adulthood, are less severe, and result from underproduction of dystrophin. Limb-girdle muscular dystrophy causes weakness in the upper limbs, usually noticeable in a person's thirties. This form of muscular dystrophy is often the result of a missing or abnormal DAG, which causes the other DAGs to be deficient too.

### Charcot-Marie-Tooth Disease—A Duplicate Gene

Charcot-Marie-Tooth disease causes a slowly progressing weakness in the muscles of the hands and feet and a decrease in tendon reflexes in these parts. In this illness, an extra gene impairs the insulating sheath around affected nerve cells, so that nerve cells cannot adequately stimulate the involved muscles. Physicians perform two tests—electromyography and nerve conduction velocities—to diagnose Charcot-Marie-Tooth disease. It is also possible to test for the gene mutation to establish a diagnosis.

### Myotonic Dystrophy—An Expanding Gene

Myotonic dystrophy delays muscle relaxation following contraction (myotonia), which causes facial and limb weakness, cataracts, and an irregular heartbeat. It is caused by inheriting either of two “expanding genes” that actually grow with each generation. As the gene enlarges, symptoms increase in severity or begin at an earlier age. For example, a grandfather might experience only mild weakness in his forearms, but his daughter might have more noticeable arm and leg weakness. By the third generation, affected children might suffer severe muscle impairment. For many years, physicians attributed the worsening of symptoms over generations to psychological causes. We now know there is a physical basis for the phenomenon. The expanded genes are transcribed into messenger RNA molecules that are too large to leave the nucleus, so that the proteins they encode are not synthesized.

### Hereditary Idiopathic Dilated Cardiomyopathy—A Tiny Glitch

This very rare inherited form of heart failure usually begins in a person's forties and is lethal in 50% of cases within five years of diagnosis, unless a heart transplant can be performed. The condition is caused by a tiny genetic error in a form of actin found only in cardiac muscle, where it is the predominant component of the thin filaments. A change in a single DNA building block (nucleotide base) disturbs actin's ability to anchor to the Z lines in heart muscle cells. The mutation prevents actin from effectively transmitting the force of contraction, which gradually causes the heart chambers to enlarge and eventually to fail.

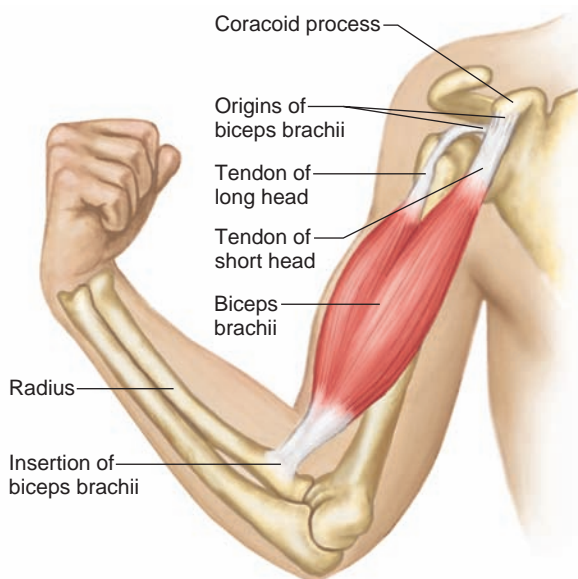
## Origin and Insertion

Recall that bones forming movable joints function as levers (see chapter 7, p. 138). One end of a skeletal muscle usually fastens to a relatively immovable or fixed part at a movable joint, and the other end connects to a movable part on the other side of that joint. The immovable end of the muscle is called its **origin** (or'ĩ-jin), and the movable end is its **insertion** (in-ser'shun). When a muscle contracts, its insertion is pulled toward its origin.

Some muscles have more than one origin or insertion. The *biceps brachii* in the arm, for example, has two origins. This is reflected in the name *biceps*, which means “two heads.” (Note: The head of a muscle is the part nearest its origin.) One head of the muscle attaches to the coracoid process of the scapula, and the other head arises from a tubercle above the glenoid cavity of the scapula. The muscle extends along the front surface of the humerus and is inserted by means of a tendon on the radial tuberosity of the radius. When the biceps brachii contracts, its insertion is pulled toward its origin, and the forearm flexes at the elbow (fig. 8.14).

The movements termed *flexion* and *extension* describe changes in the angle between bones that meet at a joint. For example, flexion of the elbow refers to a movement of the forearm that bends the elbow, or decreases the angle. Alternatively, one could say that flexion of the elbow results from the action of the biceps brachii on the radius of the forearm.

Since students often find it helpful to think of movements in terms of the specific actions of the muscles involved, we may also describe flexion and extension in



**Figure 8.14**

The biceps brachii has two heads that originate on the scapula. A tendon inserts this muscle on the radius.

these terms. Thus, the action of the biceps brachii may be described as “flexion of the forearm at the elbow,” and the action of the quadriceps group as “extension of the leg at the knee.” We believe this occasional departure from strict anatomical terminology eases understanding and learning.

## Interaction of Skeletal Muscles

Skeletal muscles almost always function in groups. Consequently, for a particular body movement to occur, a person must do more than contract a single muscle; instead, after learning to make a particular movement, the person wills the movement to occur, and the nervous system stimulates the appropriate group of muscles.

Careful observation of body movements indicates the special roles of muscles. For instance, when the upper limb is lifted horizontally away from the side, a contracting *deltoid* muscle provides most of the movement and is said to be the **prime mover** (prīm mōōv'er), also referred to as an **agonist** (ag'o-nist). However, while a prime mover is acting, certain nearby muscles are also contracting. In the case of the contracting deltoid muscle, nearby muscles help hold the shoulder steady and in this way make the prime mover's action more effective. Muscles that contract and assist the prime mover are called **synergists** (sin'er-jistz).

Certain muscles act as **antagonists** (an-tag'o-nistz) to prime movers. These muscles can resist a prime mover's action and cause movement in the opposite direction. For example, the antagonist of the prime mover that raises the upper limb can lower the upper limb, or the antagonist of the prime mover that bends the upper limb can straighten it (see fig. 7.7, p. 138). If both a prime mover and its antagonist contract simultaneously, the part they act upon remains rigid. Consequently, smooth body movements depend on antagonists relaxing and, thus, giving way to the prime movers whenever the prime movers contract. Once again, the nervous system controls these complex actions.

Sometimes the relationship between two muscles changes. For example, the pectoralis major and latissimus dorsi are antagonistic for flexion and extension of the shoulder. However, they are synergistic for medial rotation of the shoulder. Thus, the role of a muscle must be learned in the context of a particular movement.

### Check Your Recall

26. Distinguish between the origin and the insertion of a muscle.
27. Define *prime mover*.
28. What is the function of a synergist? An antagonist?



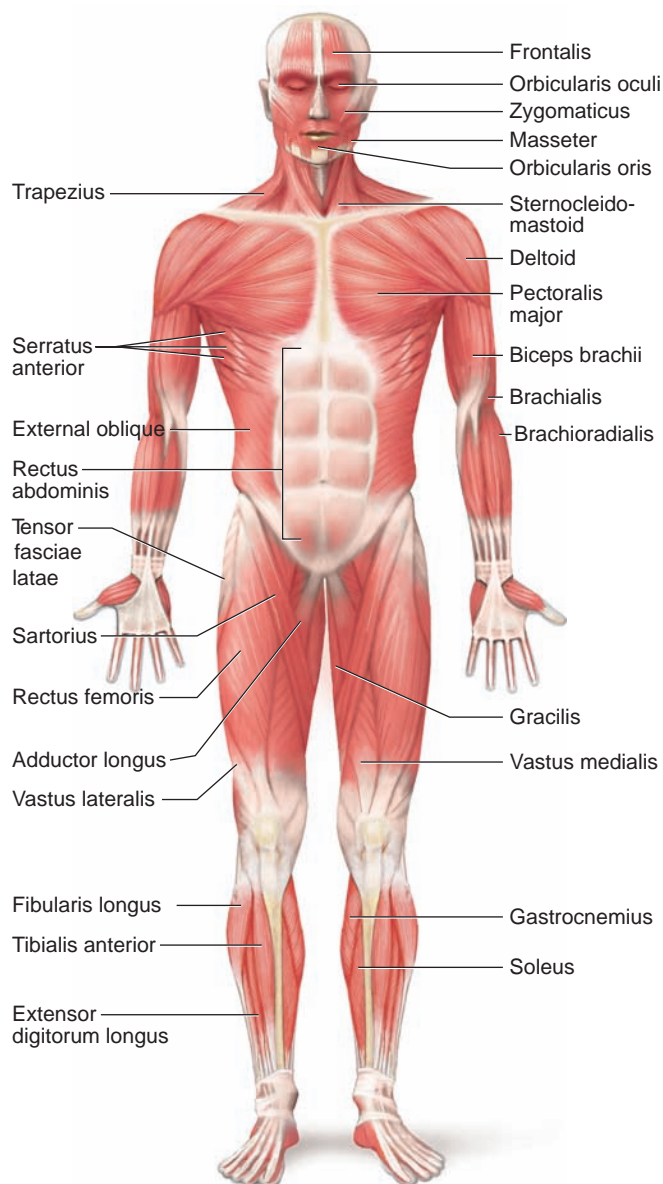
## 8.8 MAJOR SKELETAL MUSCLES

The section that follows discusses the locations, actions, and attachments of some of the major skeletal muscles. (Figures 8.15 and 8.16 and reference plates 1 and 2, pp. 23–24, show the locations of the superficial skeletal muscles—those near the surface.)

Note that the names of these muscles often describe them. A name may indicate a muscle's relative size, shape, location, action, number of attachments, or the direction of its fibers, as in the following examples:

**pectoralis major** Of large size (major) and located in the pectoral region (chest).

**deltoid** Shaped like a delta or triangle.



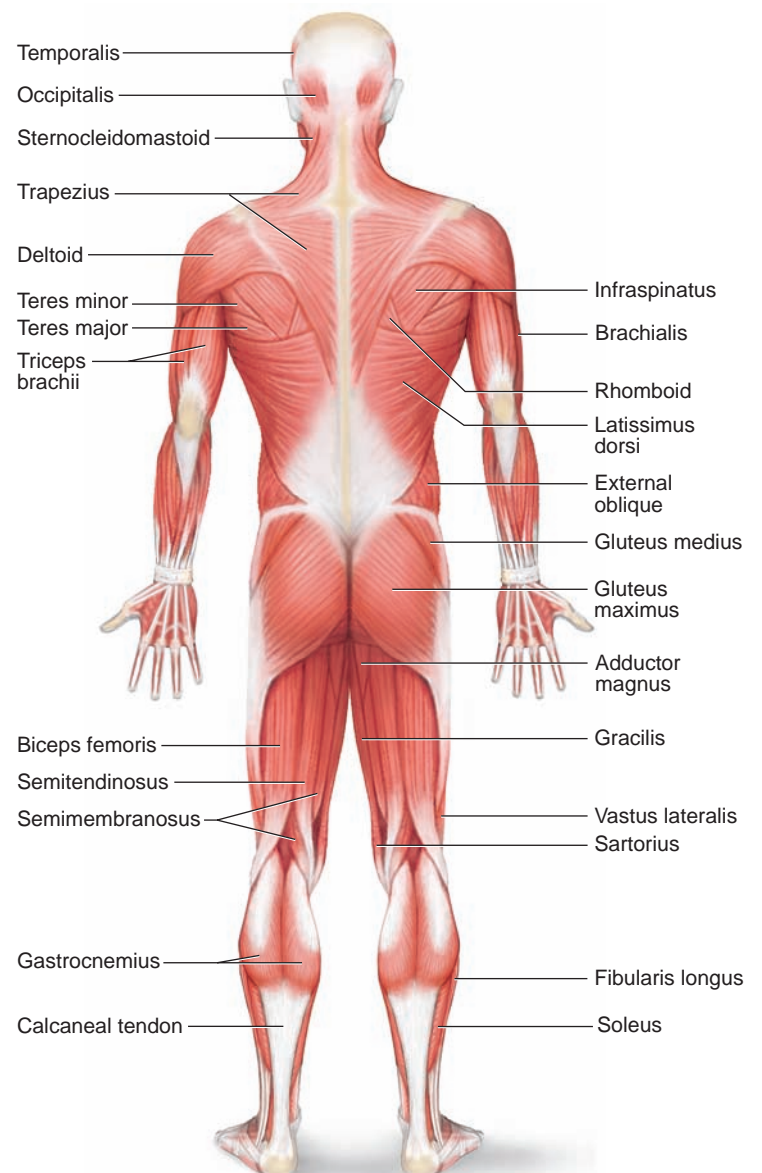
**Figure 8.15**

Anterior view of superficial skeletal muscles.

**extensor digitorum** Extends the digits (fingers or toes).  
**biceps brachii** Having two heads (biceps) or points of origin and located in the brachium (arm).  
**sternocleidomastoid** Attached to the sternum, clavicle, and mastoid process.  
**external oblique** Located near the outside, with fibers that run obliquely (in a slanting direction).

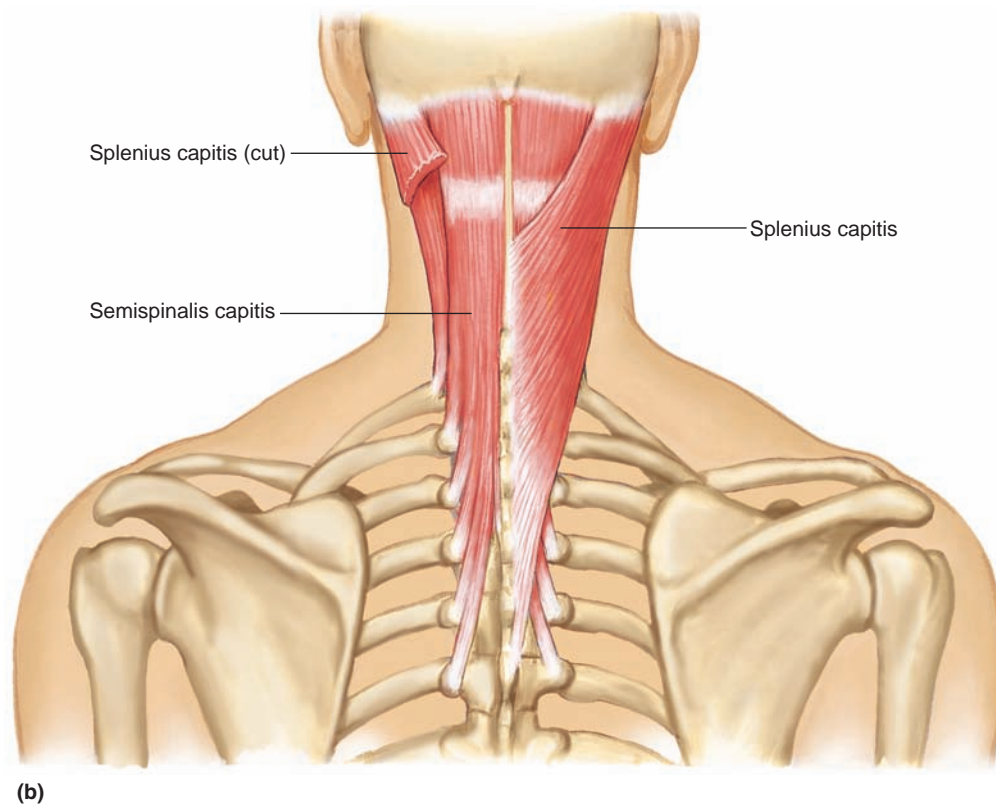
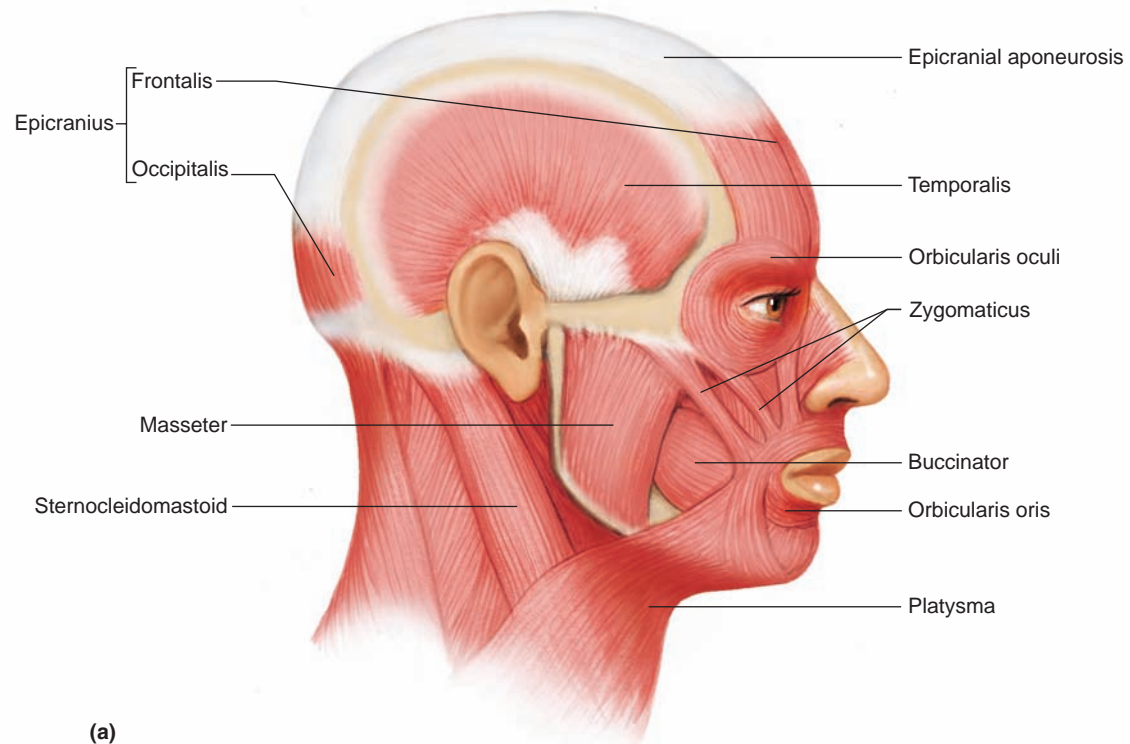
### Muscles of Facial Expression

A number of small muscles that lie beneath the skin of the face and scalp enable us to communicate feelings through facial expression (fig. 8.17*a*). Many of these muscles, located around the eyes and mouth, are responsible for such expressions as surprise, sadness,



**Figure 8.16**

Posterior view of superficial skeletal muscles.



**Figure 8.17**

Muscles of the face and neck. (a) Muscles of facial expression and mastication. (b) Posterior view of muscles that move the head.

anger, fear, disgust, and pain. As a group, the muscles of facial expression join the bones of the skull to connective tissue in various regions of the overlying skin. They include:

*epicranii* (ep"i-kra'ne-us) Composed of two parts, the *frontalis* (frun-ta'lis) and the *occipitalis* (ok-sip"i-ta'lis).

*orbicularis oculi* (or-bik'u-la-rus ok'u-li)


*orbicularis oris* (or-bik'u-la-rus o'ris)

*buccinator* (buk'si-na'tor)

*zygomaticus* (zi'go-mat'ik-us)

*platysma* (plah-tiz'mah)

Table 8.4 lists the origins, insertions, and actions of the muscles of facial expression. (The muscles that move the eyes are listed in chapter 10, pp. 277–278.)



The human body has more than 600 distinct skeletal muscles. The face alone includes 60 muscles, more than 40 of which are used to frown, and 20 to smile. Thinner than a thread and barely visible, the stapedius in the middle ear is the body's smallest muscle. In contrast is the gluteus maximus, the largest muscle, located in the buttock. The sartorius, which pulls on the thigh, is the longest muscle in the body.

## Muscles of Mastication

Muscles attached to the mandible produce chewing movements. Two pairs of these muscles elevate the mandible, a motion used in biting. These muscles are

the *masseter* (mas-se'ter) and the *temporalis* (tem-po-ra'lis) (fig. 8.17a). Table 8.5 lists the origins, insertions, and actions of the muscles of mastication. The Topic of Interest on page 196 describes a recently identified muscle thought to be associated with chewing.

Grinding the teeth, a common response to stress, may strain the temporomandibular joint—the articulation between the mandibular condyle of the mandible and the mandibular fossa of the temporal bone. This condition, called temporomandibular joint syndrome (TMJ syndrome), may produce headache, earache, and pain in the jaw, neck, or shoulder.

## Muscles That Move the Head

Head movements result from the actions of paired muscles in the neck and upper back. These muscles flex, extend, and rotate the head. They include (fig. 8.17):

*sternocleidomastoid* (ster"no-kli"do-mas'toid)

*splenius capitis* (sple'ne-us kap'i-tis)

*semispinalis capitis* (sem"e-spi-na'lis kap'i-tis)

Table 8.6 lists the origins, insertions, and actions of muscles that move the head.

## Muscles That Move the Pectoral Girdle

The muscles that move the pectoral girdle are closely associated with those that move the arm. A number of these chest and shoulder muscles connect the scapula to nearby bones and move the scapula upward, downward, forward, and backward. They include (figs. 8.18 and 8.19):

**Table 8.4** Muscles of Facial Expression

Muscle	Origin	Insertion	Action
Epicranii	Occipital bone	Skin and muscles around eye	Raises eyebrow
Orbicularis oculi	Maxillary and frontal bones	Skin around eye	Closes eye
Orbicularis oris	Muscles near the mouth	Skin of lips	Closes and protrudes lips
Buccinator	Outer surfaces of maxilla and mandible	Orbicularis oris	Compresses cheeks inward
Zygomaticus	Zygomatic bone	Orbicularis oris	Raises corner of mouth
Platysma	Fascia in upper chest	Lower border of mandible	Draws angle of mouth downward

**Table 8.5** Muscles of Mastication

Muscle	Origin	Insertion	Action
Masseter	Lower border of zygomatic arch	Lateral surface of mandible	Elevates mandible
Temporalis	Temporal bone	Coronoid process and lateral surface of mandible	Elevates mandible

## Topic of Interest



## A New Muscle Discovered?

An unusual view of a cadaver provided a new perspective that may have revealed a previously undiscovered muscle. Two dentists were examining a cadaver's skull whose eyes had been dissected out when they discovered what they believe is a new muscle in the head. The muscle, named the *sphenomandibularis*, extends about an inch and a half from behind the eyes to the inside of the jawbone and may help produce the movements of chewing. The muscle has a unique combination of the five characteristics of muscles: origin, insertion, innervation, blood vessel supply, and specific function.

In traditional dissection from the side, the new muscle's origin and insertion are not visible, so it may have appeared

to be part of the larger and overlying temporalis muscle. Although the sphenomandibularis inserts on the inner side of the jawbone, as does the temporalis, it originates differently, on the sphenoid bone.

Following their discovery of the sphenomandibularis in the cadaver head, the dentists quickly identified it in twenty-five other cadavers, and by using computer-aided dissection of the Visible Human data sets, which are collections of scans and sectioned images of the human body. Other researchers soon found it in live patients undergoing magnetic resonance imaging scans. The discovery of a new muscle illustrates that anatomy is an ever-changing science.

*trapezius* (trah-pe'ze-us)

*rhomboideus major* (rom-boid')

*levator scapulae* (le-va'tor scap'u-lē)

*serratus anterior* (ser-ra'tus an-te're-or)

*pectoralis minor* (pek'to-ra'lis)

Table 8.7 lists the origins, insertions, and actions of the muscles that move the pectoral girdle.

## Muscles That Move the Arm

The arm is one of the more freely movable parts of the body. Muscles that connect the humerus to various regions of the pectoral girdle, ribs, and vertebral column make these movements possible (figs. 8.18, 8.19, 8.20, and 8.21). These muscles can be grouped according to their

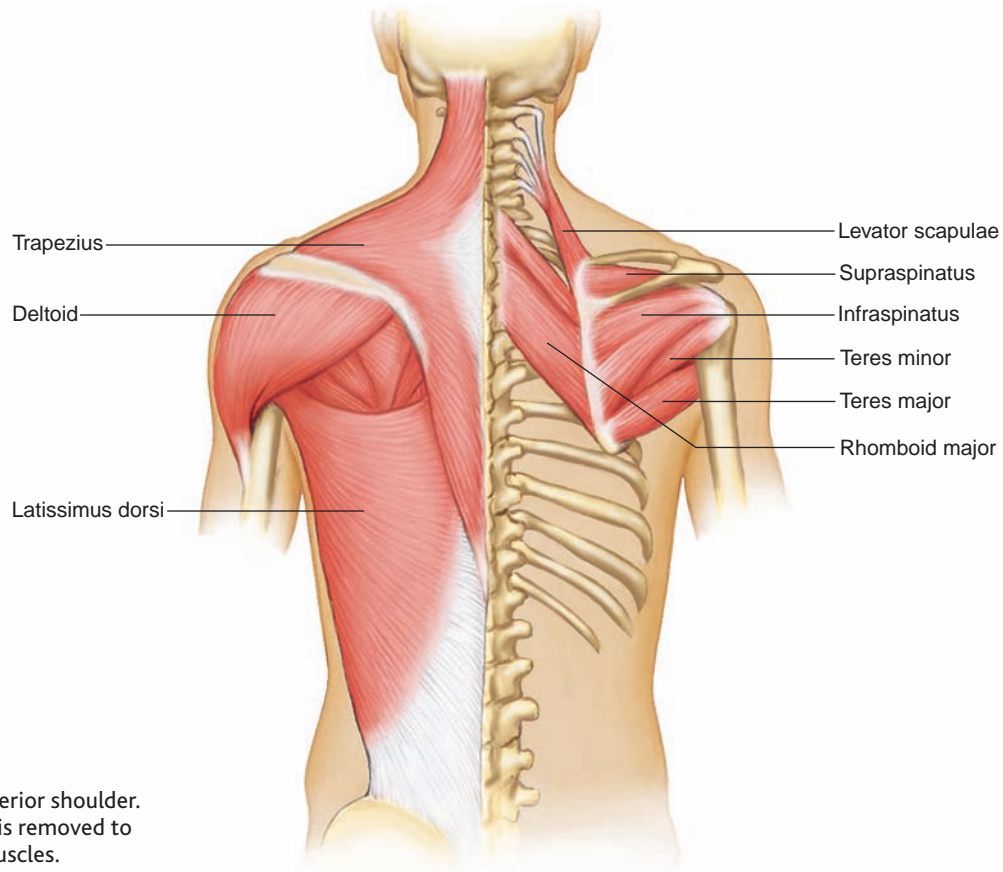
**Table 8.6** Muscles That Move the Head

Muscle	Origin	Insertion	Action
Sternocleidomastoid	Anterior surface of sternum and upper surface of clavicle	Mastoid process of temporal bone	Pulls head to one side, pulls head toward chest, or raises sternum
Splenius capitis	Spinous processes of lower cervical and upper thoracic vertebrae	Mastoid process of temporal bone	Rotates head, bends head to one side, or brings head into an upright position
Semispinalis capitis	Processes of lower cervical and upper thoracic vertebrae	Occipital bone	Extends head, bends head to one side, or rotates head

**Table 8.7** Muscles That Move the Pectoral Girdle

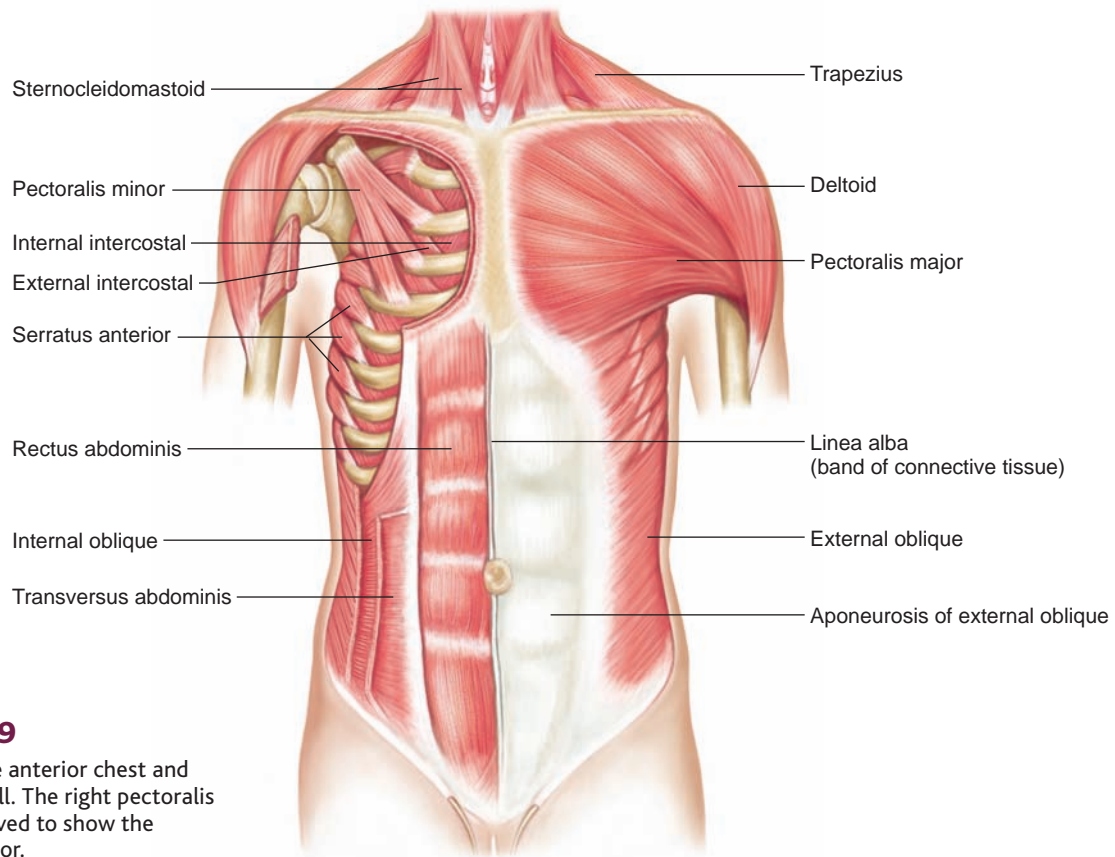
Muscle	Origin	Insertion	Action
Trapezius	Occipital bone and spines of cervical and thoracic vertebrae	Clavicle; spine and acromion process of scapula	Rotates scapula and raises arm; raises scapula; pulls scapula medially or pulls scapula and shoulder downward
Rhomboideus major	Spines of upper thoracic vertebrae	Medial border of scapula	Raises and adducts scapula
Levator scapulae	Transverse processes of cervical vertebrae	Medial margin of scapula	Elevates scapula
Serratus anterior	Outer surfaces of upper ribs	Ventral surface of scapula	Pulls scapula anteriorly and downward
Pectoralis minor	Sternal ends of upper ribs	Coracoid process of scapula	Pulls scapula anteriorly and downward or raises ribs





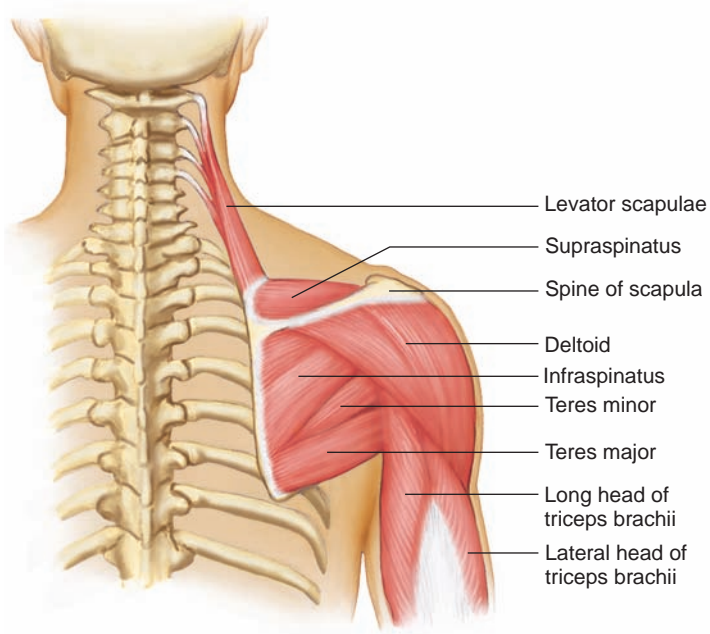
**Figure 8.18**

Muscles of the posterior shoulder. The right trapezius is removed to show underlying muscles.



**Figure 8.19**

Muscles of the anterior chest and abdominal wall. The right pectoralis major is removed to show the pectoralis minor.

**Figure 8.20**

Muscles of the posterior surface of the scapula and arm.

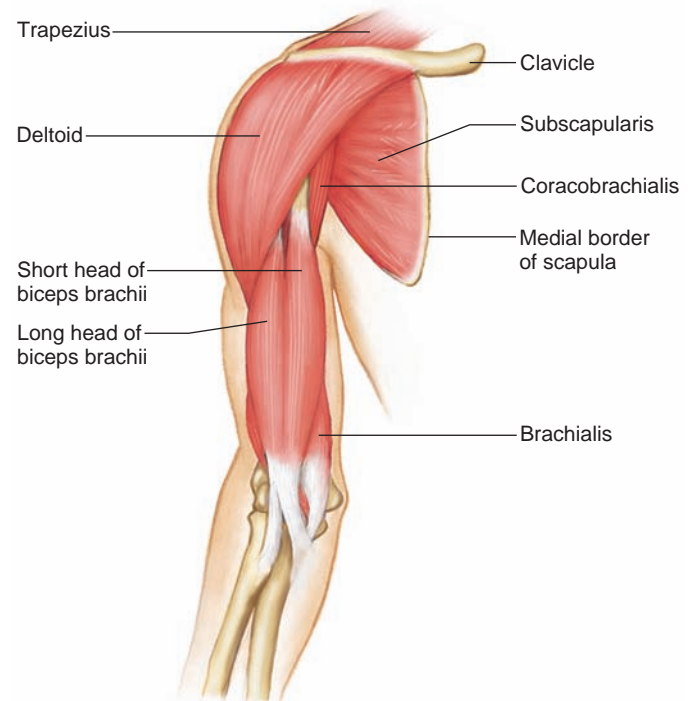
primary actions—flexion, extension, abduction, and rotation—as follows:

**Flexors**

*coracobrachialis* (kor"ah-ko-bra'ke-al-is)  
*pectoralis major* (pek"to-ra'lis)

**Extensors**

*teres major* (te'rēz)  
*latissimus dorsi* (lah-tis'ī-mus dor'si)

**Figure 8.21**

Muscles of the anterior shoulder and arm, with the rib cage removed.

**Abductors**

*supraspinatus* (su"prah-spi'na-tus)  
*deltoid* (del'toid)

**Rotators**

*subscapularis* (sub-scap'u-lar-is)  
*infraspinatus* (in"frah-spi'na-tus)  
*teres minor* (te'rēz)

Table 8.8 lists the origins, insertions, and actions of muscles that move the arm.

<b>Table 8.8</b>		<b>Muscles That Move the Arm</b>		
<b>Muscle</b>	<b>Origin</b>	<b>Insertion</b>	<b>Action</b>	
Coracobrachialis	Coracoid process of scapula	Shaft of humerus	Flexes and adducts arm	
Pectoralis major	Clavicle, sternum, and costal cartilages of upper ribs	Intertubercular groove of humerus	Pulls arm anteriorly and across chest, rotates humerus, or adducts arm	
Teres major	Lateral border of scapula	Intertubercular groove of humerus	Extends humerus or adducts and rotates arm medially	
Latissimus dorsi	Spines of sacral, lumbar, and lower thoracic vertebrae, iliac crest, and lower ribs	Intertubercular groove of humerus	Extends and adducts arm and rotates humerus inwardly, or pulls shoulder downward and posteriorly	
Supraspinatus	Posterior surface of scapula	Greater tubercle of humerus	Abducts arm	
Deltoid	Acromion process, spine of scapula, and clavicle	Deltoid tuberosity of humerus	Abducts arm, extends or flexes humerus	
Subscapularis	Anterior surface of scapula	Lesser tubercle of humerus	Rotates arm medially	
Infraspinatus	Posterior surface of scapula	Greater tubercle of humerus	Rotates arm laterally	
Teres minor	Lateral border of scapula	Greater tubercle of humerus	Rotates arm laterally	

## Muscles That Move the Forearm

Muscles that connect the radius or ulna to the humerus or pectoral girdle produce most of the forearm movements. A group of muscles located along the anterior surface of the humerus flexes the elbow, and a single posterior muscle extends this joint. Other muscles move the radioulnar joint and rotate the forearm.

Muscles that move the forearm include (figs. 8.20, 8.21, and 8.22):

### Flexors

*biceps brachii* (bi'seps bra'ke-i)

*brachialis* (bra'ke-al-is)

*brachioradialis* (bra''ke-o-ra''de-a'lis)

### Extensor

*triceps brachii* (tri'seps bra'ke-i)

### Rotators

*supinator* (su'pī-na-tor)

*pronator teres* (pro-na'tor te'rēz)

*pronator quadratus* (pro-na'tor kwod-ra'tus)

Table 8.9 lists the origins, insertions, and actions of muscles that move the forearm.

## Muscles That Move the Hand

Many muscles move the hand. They originate from the distal end of the humerus and from the radius and ulna. The two major groups of these muscles are flexors on the anterior side of the forearm and extensors on the posterior side. These muscles include (figs. 8.22 and 8.23):

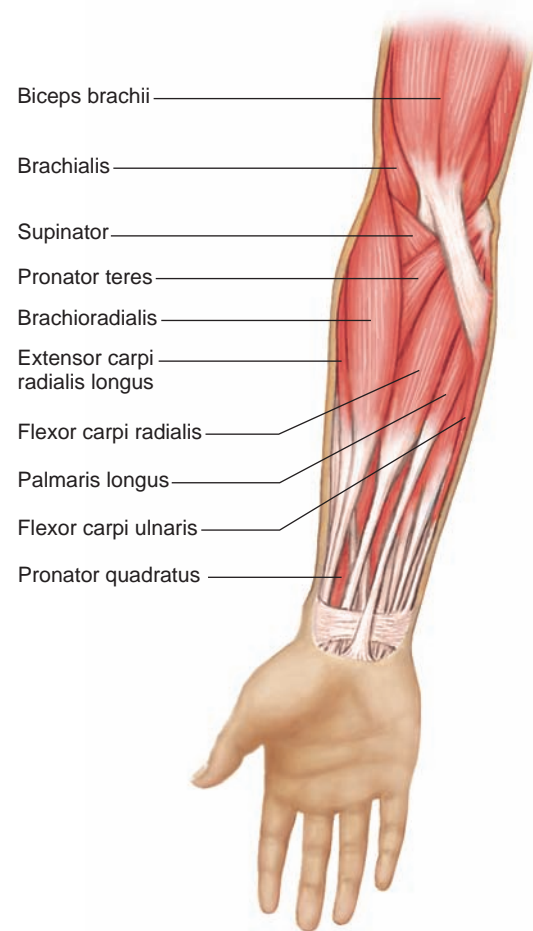
### Flexors

*flexor carpi radialis* (flex'sor kar-pi' ra''de-a'lis)

*flexor carpi ulnaris* (flex'sor kar-pi' ul-na'ris)

*palmaris longus* (pal-ma'ris long'gus)

*flexor digitorum profundus* (flex'sor dij''i-to'rum pro-fun'dus)



**Figure 8.22**

Muscles of the anterior forearm.

### Extensors

*extensor carpi radialis longus* (eks-ten'sor kar-pi' ra''de-a'lis long'gus)

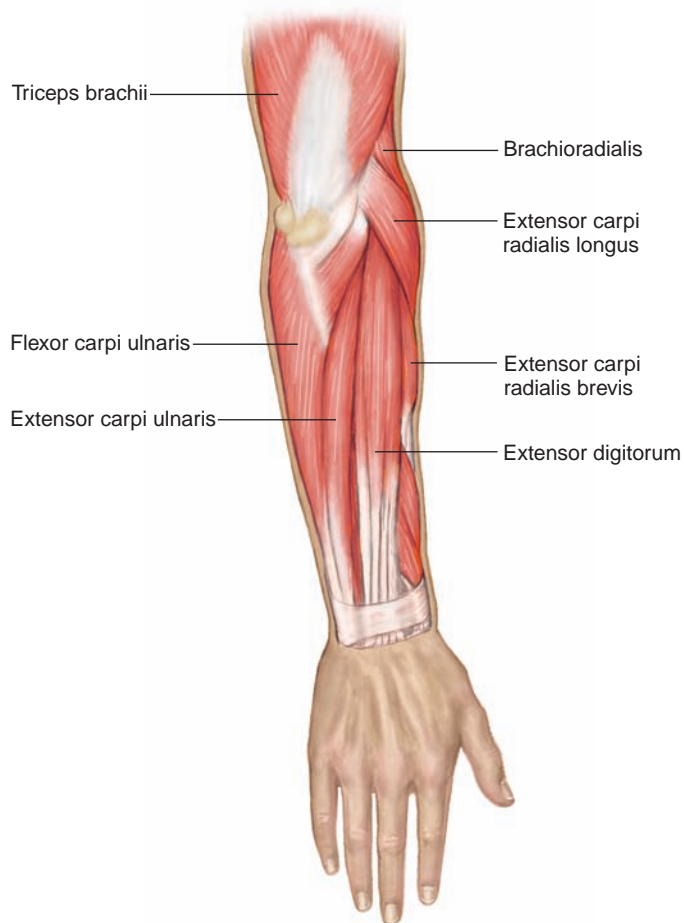
*extensor carpi radialis brevis* (eks-ten'sor kar-pi' ra''de-a'lis brev'is)

*extensor carpi ulnaris* (eks-ten'sor kar-pi' ul-na'ris)

*extensor digitorum* (eks-ten'sor dij''i-to'rum)

**Table 8.9** Muscles That Move the Forearm

Muscle	Origin	Insertion	Action
Biceps brachii	Coracoid process and tubercle above glenoid cavity of scapula	Radial tuberosity of radius	Flexes forearm at elbow and rotates hand laterally
Brachialis	Anterior shaft of humerus	Coronoid process of ulna	Flexes forearm at elbow
Brachioradialis	Distal lateral end of humerus	Lateral surface of radius above styloid process	Flexes forearm at elbow
Triceps brachii	Tubercle below glenoid cavity and lateral and medial surfaces of humerus	Olecranon process of ulna	Extends forearm at elbow
Supinator	Lateral epicondyle of humerus and crest of ulna	Lateral surface of radius	Rotates forearm laterally
Pronator teres	Medial epicondyle of humerus and coronoid process of ulna	Lateral surface of radius	Rotates forearm medially
Pronator quadratus	Anterior distal end of ulna	Anterior distal end of radius	Rotates forearm medially



**Figure 8.23**  
Muscles of the posterior forearm.

Table 8.10 lists the origins, insertions, and actions of muscles that move the hand.

## Muscles of the Abdominal Wall

Bone supports the walls of the chest and pelvic regions, but not those of the abdomen. Instead, the anterior and lateral walls of the abdomen are composed of layers of broad, flattened muscles. These muscles connect the rib cage and vertebral column to the pelvic girdle. A band of tough connective tissue called the **linea alba** extends from the xiphoid process of the sternum to the symphysis pubis (see fig. 8.19). It is an attachment for some of the abdominal wall muscles.

Contraction of these muscles decreases the size of the abdominal cavity and increases the pressure inside. These actions help press air out of the lungs during forceful exhalation and aid in the movements of defecation, urination, vomiting, and childbirth.

The abdominal wall muscles include (see fig. 8.19):

*external oblique* (eks-ter'nal o-blék')

*internal oblique* (in-ter'nal o-blék')

*transversus abdominis* (trans-ver'sus ab-dom'ĩ-nis)

*rectus abdominis* (rek'tus ab-dom'ĩ-nis)

Table 8.11 lists the origins, insertions, and actions of muscles of the abdominal wall.

## Muscles of the Pelvic Outlet

Two muscular sheets—a deeper **pelvic diaphragm** and a more superficial **urogenital diaphragm**—span the outlet of the pelvis. The pelvic diaphragm forms the floor of the pelvic cavity, and the urogenital diaphragm fills the space within the pubic arch (see fig. 7.29, p. 159). The muscles of the male and female pelvic outlets include (fig. 8.24):

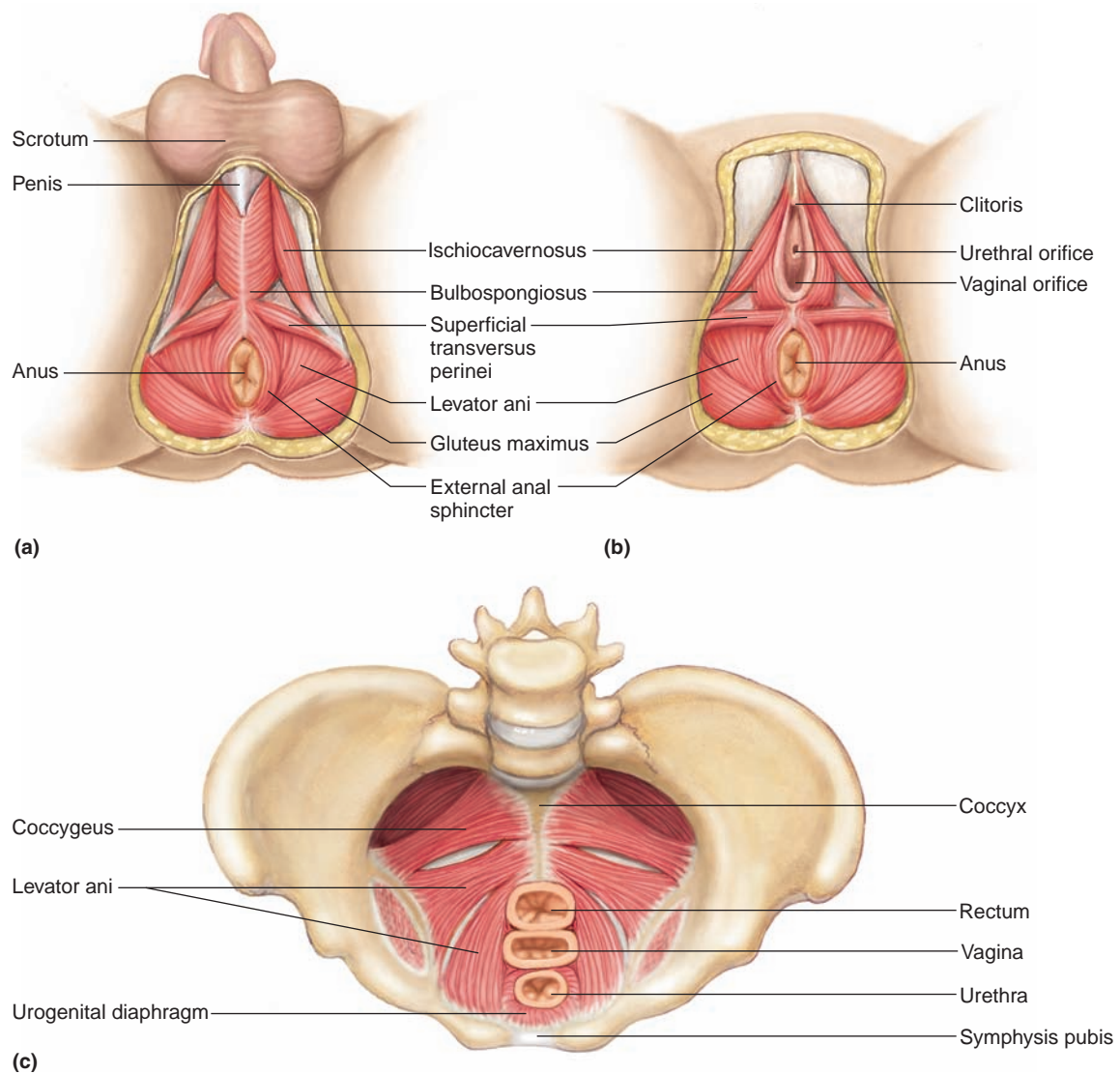
**Table 8.10** Muscles That Move the Hand

Muscle	Origin	Insertion	Action
Flexor carpi radialis	Medial epicondyle of humerus	Base of second and third metacarpals	Flexes and abducts wrist
Flexor carpi ulnaris	Medial epicondyle of humerus and olecranon process	Carpal and metacarpal bones	Flexes and adducts wrist
Palmaris longus	Medial epicondyle of humerus	Fascia of palm	Flexes wrist
Flexor digitorum profundus	Anterior surface of ulna	Bases of distal phalanges in fingers 2–5	Flexes distal joints of fingers
Extensor carpi radialis longus	Distal end of humerus	Base of second metacarpal	Extends wrist and abducts hand
Extensor carpi radialis brevis	Lateral epicondyle of humerus	Base of second and third metacarpals	Extends wrist and abducts hand
Extensor carpi ulnaris	Lateral epicondyle of humerus	Base of fifth metacarpal	Extends and adducts wrist
Extensor digitorum	Lateral epicondyle of humerus	Posterior surface of phalanges in fingers 2–5	Extends fingers



**Table 8.11** Muscles of the Abdominal Wall

Muscle	Origin	Insertion	Action
External oblique	Outer surfaces of lower ribs	Outer lip of iliac crest and linea alba	Tenses abdominal wall and compresses abdominal contents
Internal oblique	Crest of ilium and inguinal ligament	Cartilages of lower ribs, linea alba, and crest of pubis	Tenses abdominal wall and compresses abdominal contents
Transversus abdominis	Costal cartilages of lower ribs, processes of lumbar vertebrae, lip of iliac crest, and inguinal ligament	Linea alba and crest of pubis	Tenses abdominal wall and compresses abdominal contents
Rectus abdominis	Crest of pubis and symphysis pubis	Xiphoid process of sternum and costal cartilages	Tenses abdominal wall and compresses abdominal contents; also flexes vertebral column

**Figure 8.24**

External view of muscles of (a) the male pelvic outlet and (b) the female pelvic outlet. (c) Internal view of the female pelvic and urogenital diaphragms.

**Pelvic diaphragm***levator ani* (le-va'tor ah-ni')**Urogenital diaphragm***superficial transversus perinei* (su''per-fish'al  
trans-ver'sus per''i-ne'i)*bulbospongiosus* (bul''bo-spon''je-o'sus)*ischiocavernosus* (is''ke-o-kav''er-no'sus)

Table 8.12 lists the origins, insertions, and actions of pelvic outlet muscles.

**Muscles That Move the Thigh**

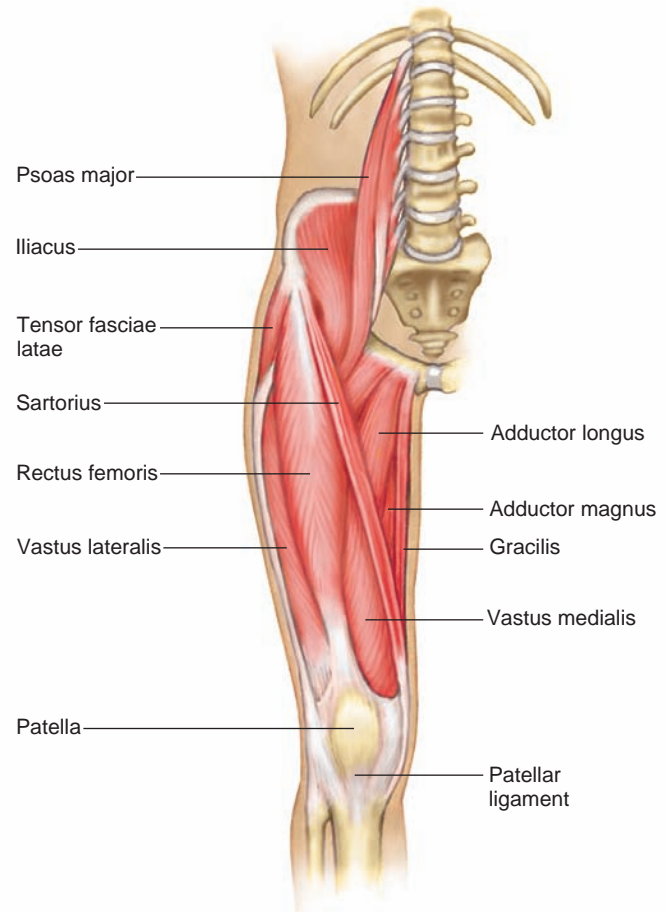
Muscles that move the thigh are attached to the femur and to some part of the pelvic girdle. These muscles occur in anterior and posterior groups. Muscles of the anterior group primarily flex the thigh; those of the posterior group extend, abduct, or rotate the thigh. The muscles in these groups include (figs. 8.25, 8.26, and 8.27):

**Anterior group***psoas major* (so'as)*iliacus* (il'e-ak-us)**Posterior group***gluteus maximus* (gloo'te-us mak'si-mus)*gluteus medius* (gloo'te-us me'de-us)*gluteus minimus* (gloo'te-us min'i-mus)*tensor fasciae latae* (ten'sor fash'e-e lah-tē)

Still another group of muscles attached to the femur and pelvic girdle adduct the thigh. They include (figs. 8.25 and 8.27):

*adductor longus* (ah-duk'tor long'gus)*adductor magnus* (ah-duk'tor mag'nus)*gracilis* (gras'il-is)

Table 8.13 lists the origins, insertions, and actions of muscles that move the thigh.

**Figure 8.25**

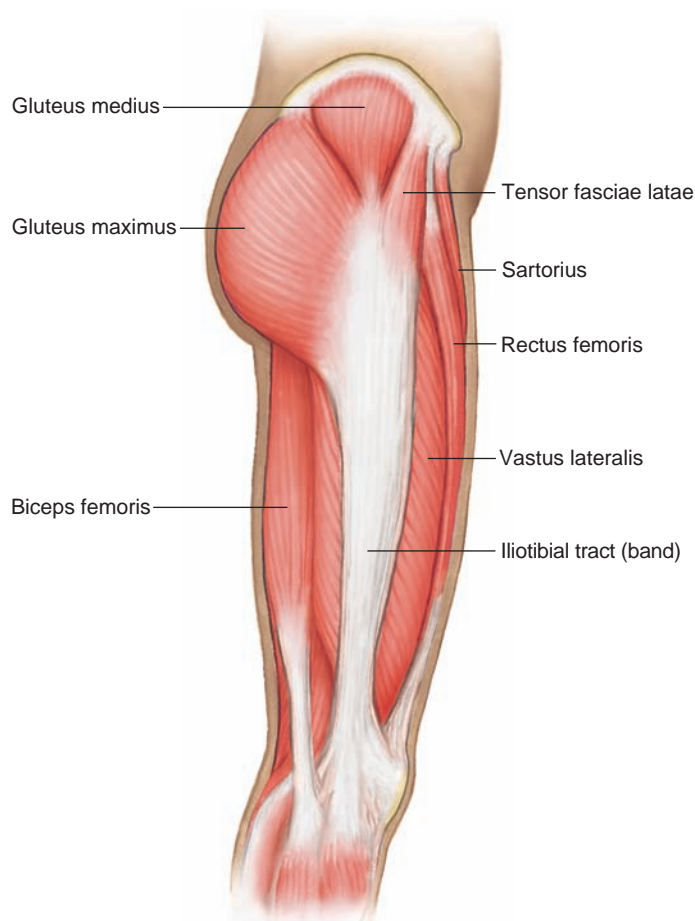
Muscles of the anterior right thigh. (Note that the vastus intermedius is a deep muscle not visible in this view.)

**Muscles That Move the Leg**

Muscles that move the leg connect the tibia or fibula to the femur or to the pelvic girdle. They can be separated into two major groups—those that flex the knee and those that extend the knee. Muscles of these groups

**Table 8.12** Muscles of the Pelvic Outlet

Muscle	Origin	Insertion	Action
Levator ani	Pubic bone and ischial spine	Coccyx	Supports pelvic viscera and provides sphincter-like action in anal canal and vagina
Superficial transversus perinei	Ischial tuberosity	Central tendon	Supports pelvic viscera
Bulbospongiosus	Central tendon	Males: Urogenital diaphragm and fascia of the penis Females: Pubic arch and root of clitoris	Males: Assists emptying of urethra Females: Constricts vagina
Ischiocavernosus	Ischial tuberosity	Pubic arch	Assists function of bulbospongiosus

**Figure 8.26**

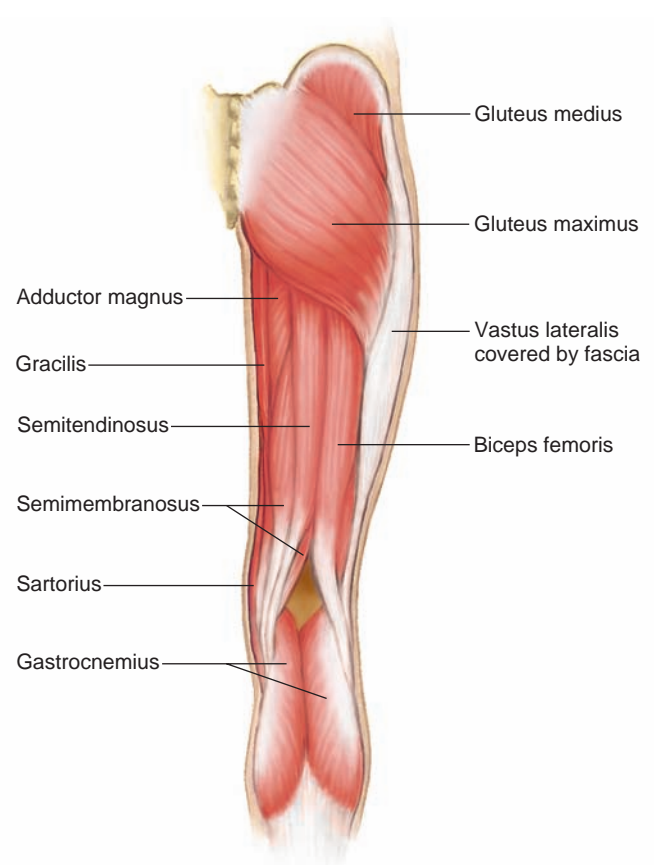
Muscles of the lateral right thigh.

include the hamstring group and the quadriceps femoris group (figs. 8.25, 8.26, and 8.27):

**Flexors**

*biceps femoris* (bi'seps fem'or-is)

*semitendinosus* (sem'e-ten'di-no-sus)

**Figure 8.27**

Muscles of the posterior right thigh.

*semimembranosus* (sem'e-mem'brah-no-sus)

*sartorius* (sar-to're-us)

**Extensor**

*quadriceps femoris group* (kwod'rī-seps fem'or-is)

Composed of four parts—the rectus femoris, vastus lateralis, vastus medialis, and vastus intermedius.

**Table 8.13** Muscles That Move the Thigh

Muscle	Origin	Insertion	Action
Psoas major	Lumbar intervertebral discs, bodies and transverse processes of lumbar vertebrae	Lesser trochanter of femur	Flexes thigh
Iliacus	Iliac fossa of ilium	Lesser trochanter of femur	Flexes thigh
Gluteus maximus	Sacrum, coccyx, and posterior surface of ilium	Posterior surface of femur and fascia of thigh	Extends thigh
Gluteus medius	Lateral surface of ilium	Greater trochanter of femur	Abducts and rotates thigh medially
Gluteus minimus	Lateral surface of ilium	Greater trochanter of femur	Abducts and rotates thigh medially
Tensor fasciae latae	Anterior iliac crest	Fascia of thigh	Abducts, flexes, and rotates thigh medially
Adductor longus	Pubic bone near symphysis pubis	Posterior surface of femur	Adducts, flexes, and rotates thigh laterally
Adductor magnus	Ischial tuberosity	Posterior surface of femur	Adducts, extends, and rotates thigh laterally
Gracilis	Lower edge of symphysis pubis	Medial surface of tibia	Adducts thigh, flexes and rotates lower limb medially

Table 8.14 lists the origins, insertions, and actions of muscles that move the leg.

## Muscles That Move the Foot

A number of muscles that move the foot are located in the leg. They attach the femur, tibia, and fibula to bones of the foot, move the foot upward (dorsiflexion) or downward (plantar flexion), and turn the sole of the foot medial (inversion) or lateral (eversion). These muscles include (figs. 8.28, 8.29, and 8.30):

### Dorsal flexors

*tibialis anterior* (tib"e-a'lis an-te're-or)

*fibularis (peroneus) tertius* (fib"u-la'ris ter'shus)

*extensor digitorum longus* (eks-ten'sor dij"i-to'rum long'gus)

### Plantar flexors

*gastrocnemius* (gas"trok-ne'me-us)

*soleus* (so'le-us)

*flexor digitorum longus* (flek'sor dij"i-to'rum long'gus)

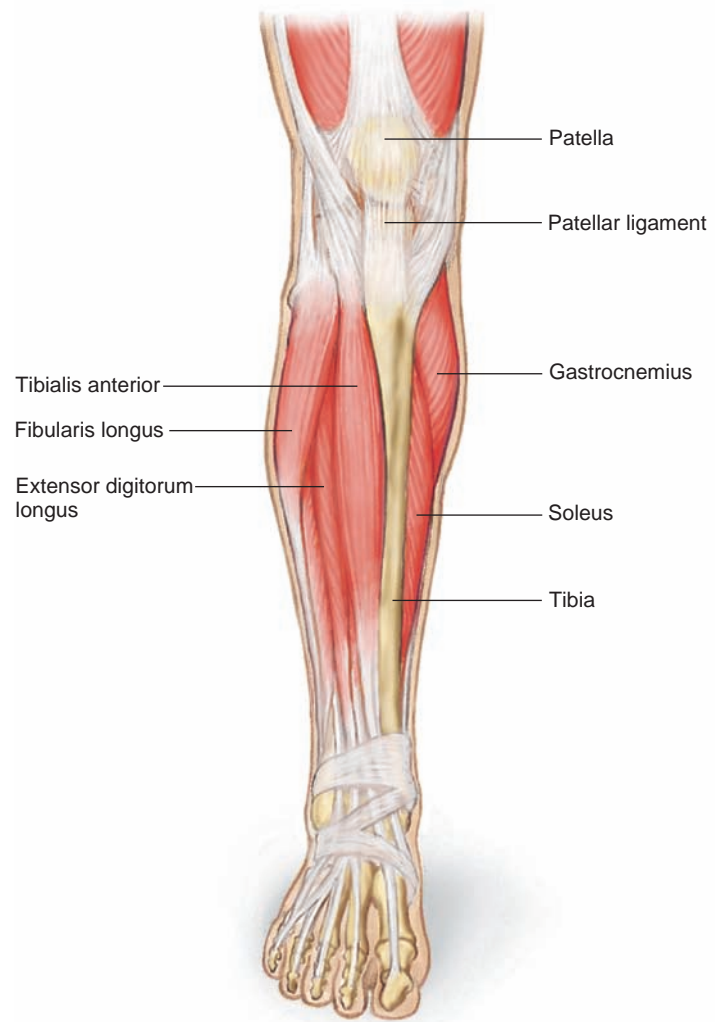
### Invertor

*tibialis posterior* (tib"e-a'lis pos-ter'e-or)

### Evertor

*fibularis (peroneus) longus* (fib"u-la'ris long'gus)

Table 8.15 lists the origins, insertions, and actions of muscles that move the foot.

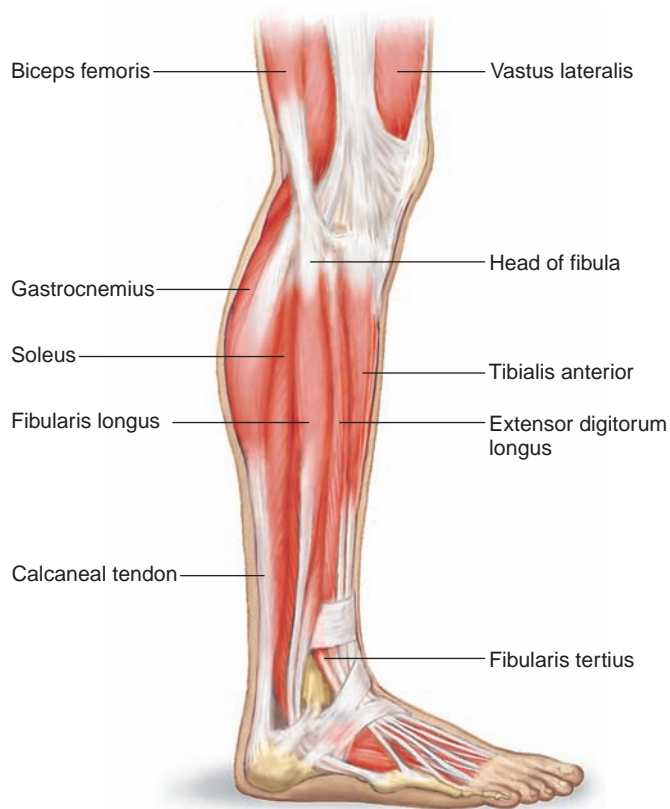


**Figure 8.28**  
Muscles of the anterior right leg.

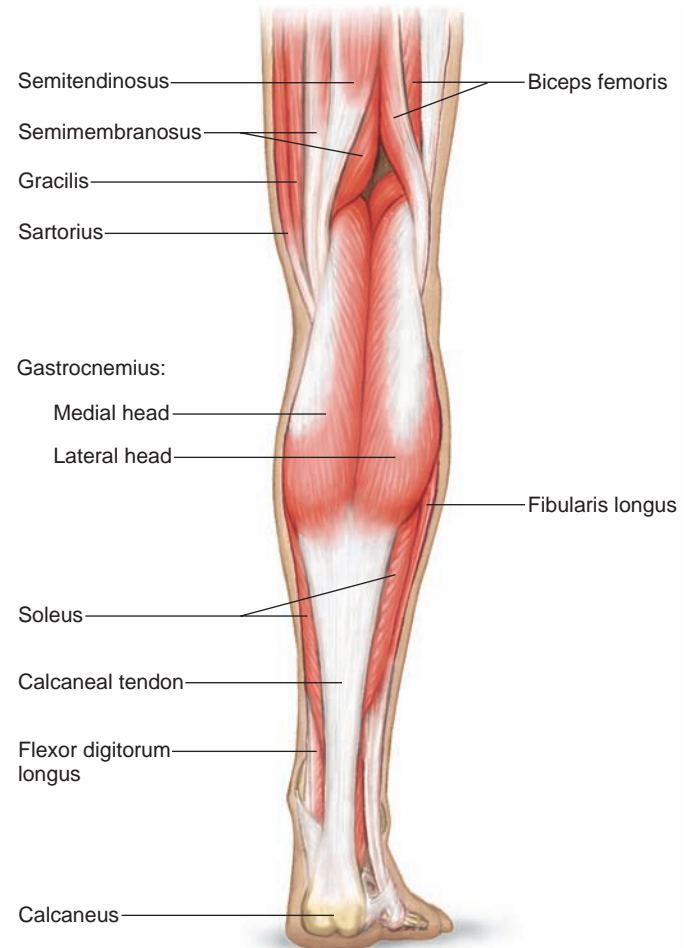
**Table 8.14** Muscles That Move the Leg

Muscle	Origin	Insertion	Action
Sartorius	Anterior superior iliac spine	Medial surface of tibia	Flexes leg and thigh, abducts thigh, rotates thigh laterally, and rotates leg medially
Hamstring group			
Biceps femoris	Ischial tuberosity and posterior surface of femur	Head of fibula and lateral condyle of tibia	Flexes leg, extends thigh
Semitendinosus	Ischial tuberosity	Medial surface of tibia	Flexes leg, extends thigh
Semimembranosus	Ischial tuberosity	Medial condyle of tibia	Flexes leg, extends thigh
Quadriceps femoris group			
Rectus femoris	Spine of ilium and margin of acetabulum	Patella by the tendon, which continues as patellar ligament to tibial tuberosity	Extends leg at knee
Vastus lateralis	Greater trochanter and posterior surface of femur	Patella by the tendon, which continues as patellar ligament to tibial tuberosity	Extends leg at knee
Vastus medialis	Medial surface of femur	Patella by the tendon, which continues as patellar ligament to tibial tuberosity	Extends leg at knee
Vastus intermedius	Anterior and lateral surfaces of femur	Patella by the tendon, which continues as patellar ligament to tibial tuberosity	Extends leg at knee



**Figure 8.29**

Muscles of the lateral right leg. (Note that the tibialis posterior is a deep muscle not visible in this view.)

**Figure 8.30**

Muscles of the posterior right leg.

**Table 8.15** Muscles That Move the Foot

Muscle	Origin	Insertion	Action
Tibialis anterior	Lateral condyle and lateral surface of tibia	Tarsal bone (cuneiform) and first metatarsal	Dorsiflexion and inversion of foot
Fibularis tertius	Anterior surface of fibula	Dorsal surface of fifth metatarsal	Dorsiflexion and eversion of foot
Extensor digitorum longus	Lateral condyle of tibia and anterior surface of fibula	Dorsal surfaces of second and third phalanges of the four lateral toes	Dorsiflexion and eversion of foot and extension of toes
Gastrocnemius	Lateral and medial condyles of femur	Posterior surface of calcaneus	Plantar flexion of foot and flexion of leg at knee
Soleus	Head and shaft of fibula and posterior surface of tibia	Posterior surface of calcaneus	Plantar flexion of foot
Flexor digitorum longus	Posterior surface of tibia	Distal phalanges of the four lateral toes	Plantar flexion and inversion of foot, and flexion of the four lateral toes
Tibialis posterior	Lateral condyle and posterior surface of tibia, and posterior surface of fibula	Tarsal and metatarsal bones	Plantar flexion and inversion of foot
Fibularis longus	Lateral condyle of tibia and head and shaft of fibula	Tarsal and metatarsal bones	Plantar flexion and eversion of foot; also supports arch

### Check Your Recall

29. What information is imparted in a muscle's name?
30. Which muscles provide facial expressions? Ability to chew? Head movements?
31. Which muscles move the pectoral girdle? Abdominal wall? Pelvic outlet? The arm, forearm, and hand? The thigh, leg, and foot?

## Clinical Terms Related to the Muscular System

**contracture** (kon-trak'cher) Condition of great resistance to the stretch of a muscle.

**convulsion** (kun-vul'shun) Series of involuntary contractions of various voluntary muscles.

**electromyography** (e-lek'tro-mi-og'rah-fe) Technique for recording electrical changes in muscle tissues.

**fibrillation** (fi'brī-la'shun) Spontaneous contractions of individual muscle fibers, producing rapid and uncoordinated activity within a muscle.

**fibrosis** (fi-bro'sis) Degenerative disease in which fibrous connective tissue replaces skeletal muscle tissue.

**fibrositis** (fi'bro-si'tis) Inflammation of fibrous connective tissues, especially in the muscle fascia. This disease is also called *muscular rheumatism*.

**muscular dystrophies** (mus'ku-lar dis'tro-fez) Group of inherited disorders in which deficiency of dystrophin or associated glycoproteins collapses muscle cells, leading to progressive loss of function.

**myalgia** (mi-al'je-ah) Pain from any muscular disease or disorder.

**myasthenia gravis** (mi'as-the'ne-ah gra'vis) Chronic disease in which muscles are weak and easily fatigued because of malfunctioning neuromuscular junctions.

**myokymia** (mi'o-ki'me-ah) Persistent quivering of a muscle.

**myology** (mi-ol'o-je) Study of muscles.

**myoma** (mi-o'mah) Tumor composed of muscle tissue.

**myopathy** (mi-op'ah-the) Any muscular disease.

**myositis** (mi'o-si'tis) Inflammation of skeletal muscle tissue.

**myotomy** (mi-ot'o-me) Cutting of muscle tissue.

**myotonia** (mi'o-to'ne-ah) Prolonged muscular spasm.

**paralysis** (pah-ral'i-sis) Loss of ability to move a body part.

**paresis** (pah-re'sis) Partial or slight paralysis of muscles.

**shin splints** (shin splints) Soreness on the front of the leg due to straining the anterior leg muscles, often as a result of walking up and down hills.

**torticollis** (tor'ti-kol'is) Condition in which the neck muscles, such as the sternocleidomastoids, contract involuntarily. It is more commonly called *wryneck*.

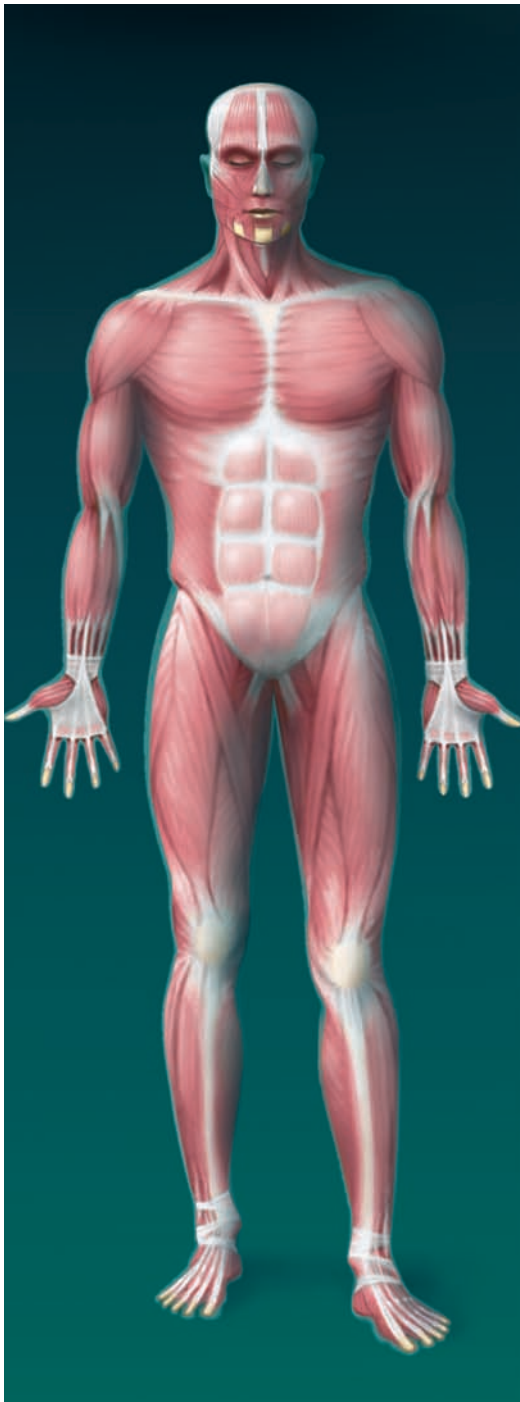
## Clinical Connection

During summer and fall in the 1940s and early 1950s, thousands of children in the United States developed a viral infection called *acute paralytic poliomyelitis*, or polio. Usually, the virus remained in the throat or the small intestine lining, or traveled to the tonsils and lymph nodes, but when it entered the spinal cord and concentrated in cells that control muscle contraction, paralysis could develop in just days. When fever first struck a child, there was no way to predict the consequences.

Polio survivors vividly recall their treatment. Because of the infectious nature of polio, patients were quarantined. Many had their limbs splinted or their entire bodies immobilized in casts; others wore braces or had surgery to restore muscle function. An early type of respirator called an iron lung enabled patients to breathe when their respiratory muscles could not work. The survivors learned to live with permanent disabilities by training other muscles to take over the functions of damaged ones. But a few decades later, people who'd had polio as children began to experience muscle weakness, great fatigue, muscle and joint pain, difficulty sleeping and breathing, and headache—the symptoms of *postpolio syndrome*. The precise cause of this new collection of symptoms isn't known.

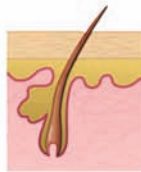Despite decades of vaccination against polio in many nations, the disease still exists, in places where vaccine was not available or used, and possibly from live vaccine strains that have mutated into pathogenic strains. The goal of the World Health Organization was to eradicate polio by the year 2000, but instead the number of cases began to rise. In 2003, more than 800 cases of polio occurred, more than half of them in northern Nigeria where people declined vaccination because they believed rumors that the United States had intentionally altered the vaccine to cause female infertility, in an attempt to control Nigerian population growth. The disease also reappeared in ten countries near Nigeria. However, widespread vaccination resumed in late 2004, following the urging of many governments. Still, the disease remains endemic in some nations and outbreaks have occurred in others. In 2006, 1,441 were reported, from Nigeria, India, Bangladesh, Pakistan, Afghanistan, Somalia, Ethiopia, Congo, and Angola.

# Muscular System



Muscles provide the force for moving body parts.

## Integumentary System



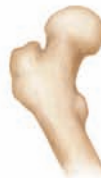The skin increases heat loss during skeletal muscle activity.

## Lymphatic System



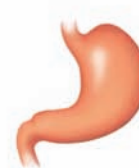Muscle action pumps lymph through lymphatic vessels.

## Skeletal System



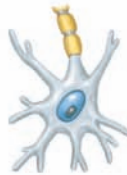Bones provide attachments that allow skeletal muscles to cause movement.

## Digestive System



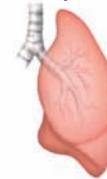Skeletal muscles are important in swallowing. The digestive system absorbs nutrients needed for muscle contraction.

## Nervous System



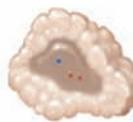Neurons control muscle contractions.

## Respiratory System



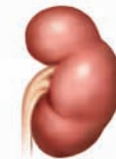Breathing depends on skeletal muscles. The lungs provide oxygen for body cells and excrete carbon dioxide.

## Endocrine System



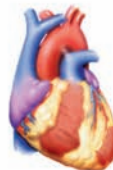Hormones help increase blood flow to exercising skeletal muscles.

## Urinary System



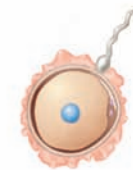Skeletal muscles help control expulsion of urine from the urinary bladder.

## Cardiovascular System



The heart pumps as a result of cardiac muscle contraction. Blood flow delivers oxygen and nutrients and removes wastes.

## Reproductive System



Skeletal muscles are important in sexual activity.

## SUMMARY OUTLINE

### 8.1 Introduction (p. 177)

*The three types of muscle tissue are skeletal, smooth, and cardiac.*

### 8.2 Structure of a Skeletal Muscle (p. 177)

*Individual muscles are the organs of the muscular system. They include skeletal muscle tissue, nervous tissue, blood, and connective tissues.*

1. Connective tissue coverings
  - a. Fascia covers skeletal muscles.
  - b. Other connective tissues attach muscles to bones or to other muscles.
  - c. A network of connective tissue extends throughout the muscular system.
2. Skeletal muscle fibers
  - a. Each skeletal muscle fiber is a single muscle cell, which is the unit of contraction.
  - b. The cytoplasm contains mitochondria, sarcoplasmic reticulum, and myofibrils of actin and myosin.
  - c. The organization of actin and myosin filaments produces striations.
  - d. Transverse tubules extend inward from the cell membrane and associate with the sarcoplasmic reticulum.
3. Neuromuscular junction
  - a. Motor neurons stimulate muscle fibers to contract.
  - b. In response to a nerve impulse, the end of a motor neuron axon secretes a neurotransmitter, which stimulates the muscle fiber to contract.
4. Motor units
  - a. One motor neuron and the muscle fibers associated with it constitute a motor unit.
  - b. All the muscle fibers of a motor unit contract together.

### 8.3 Skeletal Muscle Contraction (p. 181)

*Muscle fiber contraction results from a sliding movement of actin and myosin filaments.*

1. Role of myosin and actin
  - a. Cross-bridges of myosin filaments form linkages with actin filaments.
  - b. The reaction between actin and myosin filaments generates the force of contraction.
2. Stimulus for contraction
  - a. Acetylcholine released from the distal end of a motor neuron axon stimulates a skeletal muscle fiber.
  - b. Acetylcholine causes the muscle fiber to conduct an impulse over the surface of the fiber that reaches deep within the fiber through the transverse tubules.
  - c. A muscle impulse signals the sarcoplasmic reticulum to release calcium ions.
  - d. Linkages form between actin and myosin, and the myosin cross-bridges pull on actin filaments, shortening the fiber.
  - e. The muscle fiber relaxes when cross-bridges release from actin (ATP is needed, but is not broken down) and when calcium ions are actively transported (requiring ATP breakdown) back into the sarcoplasmic reticulum.
  - f. Acetylcholinesterase breaks down acetylcholine.
3. Energy sources for contraction
  - a. ATP supplies the energy for muscle fiber contraction.
  - b. Creatine phosphate stores energy that can be used to synthesize ATP.
  - c. ATP is needed for muscle relaxation.
4. Oxygen supply and cellular respiration
  - a. Aerobic respiration requires oxygen.

- b. Red blood cells carry oxygen to body cells.
  - c. Myoglobin in muscle cells temporarily stores oxygen.
5. Oxygen debt
    - a. During rest or moderate exercise, muscles receive enough oxygen to respire aerobically.
    - b. During strenuous exercise, oxygen deficiency may cause lactic acid to accumulate.
    - c. Oxygen debt is the amount of oxygen required to convert accumulated lactic acid to glucose and to restore supplies of ATP and creatine phosphate.
  6. Muscle fatigue
    - a. A fatigued muscle loses its ability to contract.
    - b. Muscle fatigue is usually due to accumulation of lactic acid.
  7. Heat production
    - a. More than half of the energy released in cellular respiration is lost as heat.
    - b. Muscle action is an important source of body heat.

### 8.4 Muscular Responses (p. 187)

1. Threshold stimulus is the minimal stimulus required to elicit a muscular contraction.
2. Recording a muscle contraction
  - a. A twitch is a single, short contraction reflecting stimulation of a muscle fiber.
  - b. A myogram is a recording of an electrically stimulated isolated muscle.
  - c. The latent period, the time between stimulus and responding muscle contraction, is followed by a period of contraction and a period of relaxation.
3. Summation
  - a. A rapid series of stimuli may produce summation of twitches.
  - b. Forceful, sustained contraction without relaxation is a tetanic contraction.
4. Recruitment of motor units
  - a. A whole muscle is composed of many motor units controlled by different motor neurons which respond to different thresholds of stimulation.
  - b. At a low intensity of stimulation, small numbers of motor units contract.
  - c. At increasing intensities of stimulation, other motor units are recruited until the muscle contracts with maximal tension.
5. Sustained contractions
  - a. Summation and recruitment together can produce a sustained contraction of increasing strength.
  - b. Even when a muscle is at rest, its fibers usually remain partially contracted.

### 8.5 Smooth Muscle (p. 189)

*The contractile mechanism of smooth muscle is similar to that of skeletal muscle.*

1. Smooth muscle fibers
  - a. Smooth muscle cells contain filaments of actin and myosin.
  - b. Types include multiunit smooth muscle and visceral smooth muscle.
  - c. Visceral smooth muscle displays rhythmicity and is self-exciting.
2. Smooth muscle contraction
  - a. Two neurotransmitters—acetylcholine and norepinephrine—and hormones affect smooth muscle function.
  - b. Smooth muscle can maintain a contraction longer with a given amount of energy than can skeletal muscle.
  - c. Smooth muscles can change length without changing tension.



## 8.6 Cardiac Muscle (p. 190)

1. Like skeletal muscle cells, cardiac muscle cells have many actin and myosin filaments.
2. Cardiac muscle twitches last longer than skeletal muscle twitches.
3. Intercalated discs connect cardiac muscle cells.
4. A network of fibers contracts as a unit.
5. Cardiac muscle is self-exciting and rhythmic.

## 8.7 Skeletal Muscle Actions (p. 190)

*The type of movement a skeletal muscle produces depends on the way the muscle attaches on either side of a joint.*

1. Origin and insertion
  - a. The immovable end of a skeletal muscle is its origin, and the movable end is its insertion.
  - b. Some muscles have more than one origin.
2. Interaction of skeletal muscles
  - a. Skeletal muscles function in groups.
  - b. A prime mover is responsible for most of a movement. Synergists aid prime movers. Antagonists can resist the action of a prime mover.
  - c. Smooth movements depend on antagonists giving way to the actions of prime movers.

## 8.8 Major Skeletal Muscles (p. 193)

1. Muscles of facial expression
  - a. These muscles lie beneath the skin of the face and scalp and are used to communicate feelings through facial expression.
  - b. They include the epicranii, orbicularis oculi, orbicularis oris, buccinator, zygomaticus, and platysma.
2. Muscles of mastication
  - a. These muscles attach to the mandible and are used in chewing.
  - b. They include the masseter and temporalis.
3. Muscles that move the head
  - a. Muscles in the neck and upper back move the head.
  - b. They include the sternocleidomastoid, splenius capitis, and semispinalis capitis.
4. Muscles that move the pectoral girdle
  - a. Most of these muscles connect the scapula to nearby bones and closely associate with muscles that move the arm.
  - b. They include the trapezius, rhomboid major, levator scapulae, serratus anterior, and pectoralis minor.
5. Muscles that move the arm
  - a. These muscles connect the humerus to various regions of the pectoral girdle, ribs, and vertebral column.
  - b. They include the coracobrachialis, pectoralis major, teres major, latissimus dorsi, supraspinatus, deltoid, subscapularis, infraspinatus, and teres minor.
6. Muscles that move the forearm
  - a. These muscles connect the radius and ulna to the humerus or pectoral girdle.
  - b. They include the biceps brachii, brachialis, brachioradialis, triceps brachii, supinator, pronator teres, and pronator quadratus.
7. Muscles that move the hand
  - a. These muscles arise from the distal end of the humerus and from the radius and ulna.
  - b. They include the flexor carpi radialis, flexor carpi ulnaris, palmaris longus, flexor digitorum profundus, extensor carpi radialis longus, extensor carpi radialis brevis, extensor carpi ulnaris, and extensor digitorum.
8. Muscles of the abdominal wall
  - a. These muscles connect the rib cage and vertebral column to the pelvic girdle.

- b. They include the external oblique, internal oblique, transversus abdominis, and rectus abdominis.
9. Muscles of the pelvic outlet
    - a. These muscles form the floor of the pelvic cavity and fill the space within the pubic arch.
    - b. They include the levator ani, superficial transversus perinei, bulbospongiosus, and ischiocavernosus.
  10. Muscles that move the thigh
    - a. These muscles attach to the femur and to some part of the pelvic girdle.
    - b. They include the psoas major, iliacus, gluteus maximus, gluteus medius, gluteus minimus, tensor fasciae latae, adductor longus, adductor magnus, and gracilis.
  11. Muscles that move the leg
    - a. These muscles connect the tibia or fibula to the femur or pelvic girdle.
    - b. They include the biceps femoris, semitendinosus, semimembranosus, sartorius, and the quadriceps femoris group.
  12. Muscles that move the foot
    - a. These muscles attach the femur, tibia, and fibula to bones of the foot.
    - b. They include the tibialis anterior, fibularis tertius, extensor digitorum longus, gastrocnemius, soleus, flexor digitorum longus, tibialis posterior, and fibularis longus.

## CHAPTER ASSESSMENTS

### 8.1 Introduction

1. The three types of muscle tissue are \_\_\_\_\_, \_\_\_\_\_, and \_\_\_\_\_. (p. 177)

### 8.2 Structure of a Skeletal Muscle

2. Describe the difference between a tendon and an aponeurosis. (p. 177)
3. Describe how connective tissue associates with skeletal muscle. (p. 177)
4. List the major parts of a skeletal muscle fiber, and describe the function of each part. (p. 177)
5. Describe a neuromuscular junction. (p. 180)
6. A neurotransmitter \_\_\_\_\_. (p. 180)
  - a. binds actin filaments, causing them to slide
  - b. travels across a synapse from a neuron to a muscle cell
  - c. ferries ATP across a synapse
  - d. travels across a synapse from a muscle cell to a neuron.
  - e. is a contractile protein that is part of a skeletal muscle fiber.
7. Define *motor unit*. (p. 180)

### 8.3 Skeletal Muscle Contraction

8. List the major events of muscle fiber contraction and relaxation. (p. 181)
9. Describe how ATP and creatine phosphate interact. (p. 183)
10. Describe how muscles obtain oxygen. (p. 184)
11. Describe how an oxygen debt may develop. (p. 184)
12. Explain how muscles may become fatigued. (p. 185)
13. Explain how skeletal muscle function affects the maintenance of body temperature. (p. 186)

### 8.4 Muscular Responses

14. Define *threshold stimulus*. (p. 187)
15. Sketch a myogram of a single muscular twitch, and identify the latent period, period of contraction, and period of relaxation. (p. 187)
16. Explain motor unit *recruitment*. (p. 188)
17. Explain how skeletal muscle stimulation produces a sustained contraction. (p. 188)

18. Distinguish between tetanic contraction and muscle tone. (p. 188)

### 8.5 Smooth Muscle

19. Distinguish between multiunit and visceral smooth muscle fibers. (p. 189)  
20. Compare smooth and skeletal muscle contractions. (p. 189)

### 8.6 Cardiac Muscle

21. Make a table comparing contraction mechanisms of cardiac and skeletal muscle fibers. (p. 190)

### 8.7 Skeletal Muscle Actions

22. Distinguish between a muscle's origin and its insertion. (p. 192)  
23. Define *prime mover*, *synergist*, and *antagonist*. (p. 192)

### 8.8 Major Skeletal Muscles

24. Match the muscles on the left to the descriptions and functions on the right. (pp. 195–205)
- |                        |   |
|------------------------|---|
| (1) Buccinator         | A. Inserted on coronoid process of mandible |
| (2) Epicranius         | B. Draws corner of mouth upward             |
| (3) Orbicularis oris   | C. Can raise and adduct scapula             |
| (4) Platysma           | D. Can pull head into an upright position   |
| (5) Rhomboid major     | E. Raises eyebrow                           |
| (6) Splenius capitis   | F. Compresses cheeks                        |
| (7) Temporalis         | G. Extends over neck from chest to face     |
| (8) Zygomaticus        | H. Closes lips                              |
| (9) Biceps brachii     | I. Extends forearm at elbow                 |
| (10) Brachialis        | J. Pulls shoulder back and downward         |
| (11) Deltoid           | K. Abducts arm                              |
| (12) Latissimus dorsi  | L. Inserted on radial tuberosity            |
| (13) Pectoralis major  | M. Pulls arm forward and across chest       |
| (14) Pronator teres    | N. Rotates forearm medially                 |
| (15) Teres minor       | O. Inserted on coronoid process of ulna     |
| (16) Triceps brachii   | P. Rotates arm laterally                    |
| (17) Biceps femoris    | Q. Inverts foot                             |
| (18) External oblique  | R. Member of quadriceps femoris group       |
| (19) Gastrocnemius     | S. Plantar flexor of foot                   |
| (20) Gluteus maximus   | T. Compresses contents of abdominal cavity  |
| (21) Gluteus medius    | U. Extends thigh                            |
| (22) Gracilis          | V. Hamstring muscle                         |
| (23) Rectus femoris    | W. Adducts thigh                            |
| (24) Tibialis anterior | X. Abducts thigh                            |
25. Which muscles can you identify in the bodies of these models? (pp. 195–205)



## INTEGRATIVE ASSESSMENTS/ CRITICAL THINKING

### OUTCOME 8.2

1. Discuss how connective tissue is part of the muscular system.

### OUTCOME 8.3

2. As lactic acid and other substances accumulate in an active muscle they stimulate pain receptors, and the muscle may feel sore. How might the application of heat or substances that dilate blood vessels relieve such soreness?

### OUTCOMES 8.3, 8.4

3. A woman takes her daughter to a sports medicine specialist and requests that she determine the percentage of fast- and slow-twitch fibers in the girl's leg muscles. The parent wants to know if the healthy girl should try out for soccer or cross-country running. Do you think this is a valid reason to test muscle tissue? Why or why not?
4. Following an injury to a nerve, the muscle it supplies with motor nerve fibers may become paralyzed. How would you explain to a patient the importance of moving the disabled muscles passively or contracting them using electrical stimulation?

### OUTCOMES 8.5, 8.8

5. What steps might be taken to minimize atrophy of the skeletal muscles in patients confined to bed for prolonged times?

## WEB CONNECTIONS

Visit the text website at [aris.mhhe.com](http://aris.mhhe.com) for additional quizzes, interactive learning exercises, and more.

## AP R MUSCULAR SYSTEM

Anatomy & Physiology | REVEALED includes cadaver photos that allow you to peel away layers of the human body to reveal structures beneath the surface. This program also includes animations, radiologic imaging, audio pronunciation, and practice quizzing. To learn more visit [www.aprevealed.com](http://www.aprevealed.com).